

Treatment of Psoriasis with
Mesenchymal Stem Cells

To the Editor:

Psoriasis is an incurable immune-mediated disease, which affects approximately 2% of the world's population. Current treatments, including newly emerged biologic agents, have some limitations.¹ Here, we report 2 cases of psoriasis vulgaris treated by umbilical cord-derived mesenchymal stem cells (UC-MSCs). In these 2 cases, both of the patients remained relapse free for 4 or 5 years.

Patient 1: On July 7, 2009, a 35-year-old man, who had suffered psoriasis for 12 years and was newly diagnosed with diffuse large B-cell lymphoma (stage IV), came to our hospital. Three cycles of standard lymphoma chemotherapies and 2 autologous hematopoietic stem cell transplantations (auto-HSCT) were performed. Before the first transplantation, the physical examination showed numerous erythematous plaques with adherent silvery scales symmetrically distributed throughout the patient's body (**Figure A.1**). The distribution of the plaques clearly decreased after both conditioning regimens were performed 2 times, yet new skin lesions appeared within 6 weeks. Moreover, after the second transplantation, the patient suffered repeated infections, with continuous fever around 38°C and unstable blood counts (white cell count was $5.27 \times 10^9/L$ with use of granulocyte colony-stimulating factor, hemoglobin was 107 g/L, platelet count was $55 \times 10^9/L$). After the patient's infection had been controlled, we gave him one dose ($1 \times 10^6/kg$) of UC-MSCs to support engraftments. Unexpectedly, his skin lesions, as well as engraftment, recovered day by day. Six months later, the patient's lymphoma underwent complete remission and his psoriasis was significantly relieved (**Figure A.2**). The skin returned to normal within 12 months (**Figure A.3**). Now the patient has been monitored for nearly 5 years. His condition remains stable, with no recurrence of lymphoma or psoriasis.

Funding: This study is supported by the "863 Projects" of China (No. 2013AA0200103); National High Tech Research and Development Program.

Conflict of Interest: None.

Authorship: All authors had access to the data and a role in writing the manuscript.

Requests for reprints should be addressed to Hu Chen, MD, PhD and Bin Zhang, MD, PhD, No. 8 Dongda Street, Fengtai District, Beijing 100071, China.

E-mail address: chenhu217@aliyun.com or zb307ctc@163.com

Patient 2: A 26-year-old woman, who was diagnosed with psoriasis vulgaris when she was 8 years old, came to our hospital in October 2011. She described how her symptoms got worse every autumn and winter after suffering psoriasis. Although topical steroidal agents could temporarily relieve her symptoms, the psoriasis still relapsed every year. Physical examinations after the patient had been admitted to our hospital showed that salmon-pink plaques were covered by silvery scales and were distributed all over the body (**Figure B.1**). Initially, we gave her 3 infusions of UC-MSCs ($1 \times 10^6/Kg$ each time) over 3 successive weeks. Gradually, her whole body surface turned smooth (**Figure B.2**). Three months later, we gave her 2 more UC-MSC infusions as consolidating therapies. The psoriasis has been relapse free for 4 years now.

MSCs are heterogeneous cells that can differentiate into various types of cells and secrete cytokines.² We gave the first patient MSCs based on 2 reasons: one is that MSCs could support hematopoiesis,³ the other is that MSCs have already been used in autoimmune diseases.⁴ Although auto-HSCT may have played a part in the release of the first patient's psoriasis, it is still under the risk of relapse.⁵ The patient who underwent auto-HSCT and UC-MSCs infusion showed no symptoms of psoriatic relapse after nearly 5 years. In addition, MSCs have a unique advantage in terms of safety. We assume that MSCs may be involved in the following 4 aspects: migration to skin lesions, immunomodulation, limitation of autoimmunity, and local paracrine effects. However, more cases are needed to determine the efficacy of MSCs and their infusion dose, method, and delivery time.

Hu Chen, MD, PhD^{a,b}

Jing-Wen Niu, MD^{a,b}

Hong-Mei Ning, MD, PhD^a

Xin Pan, MD^a

Xiao-Bin Li, PhD^c

Yu Li, MD^d

Dan-Hong Wang, MD^a

Liang-Ding Hu, MD^a

Hong-Xia Sheng, MS^b

Man Xu, MS^b

Li Zhang, MD, PhD^d

Bin Zhang, MD, PhD^{a,b}

^aDepartment of Hematopoietic Stem Cell Transplantation
Affiliated Hospital of Academy of Military Medical Sciences
Beijing, China

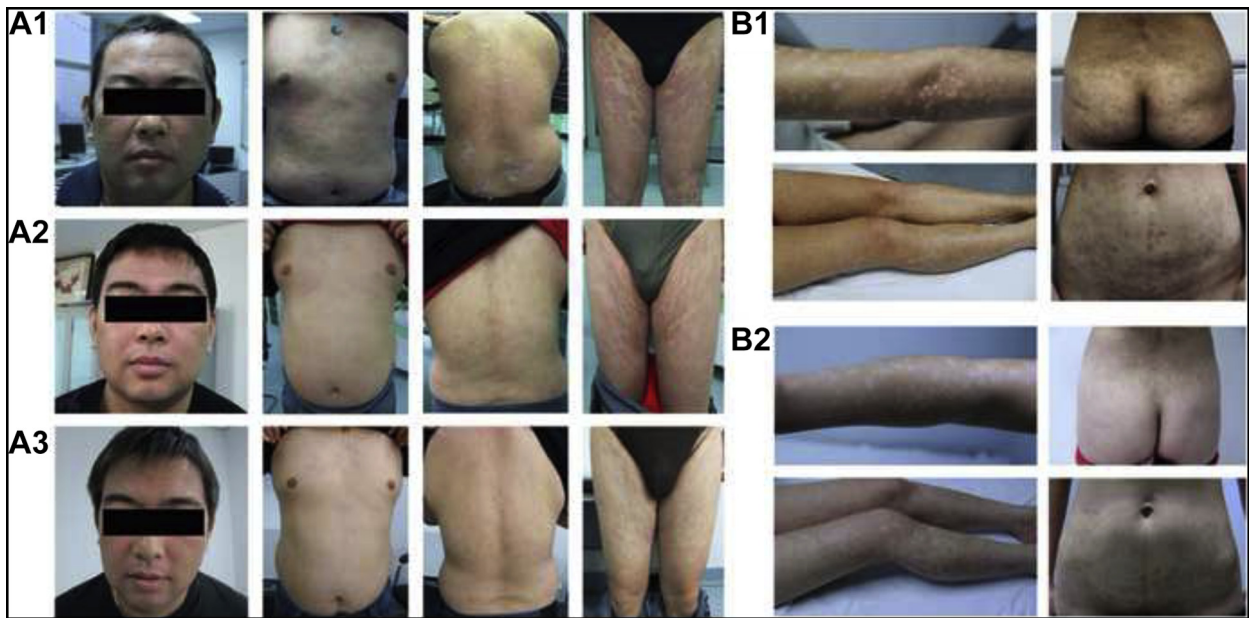


Figure Clinical images. (A) Patient no. 1: (A1) Pre UC-MSCs infusions: well-defined erythematous plaques with adherent silvery scales symmetrically distributed throughout the body, mainly including the forehead, face, upper chest, abdomen, back, and legs; (A2) Six months after UC-MSCs infusion; (A3) Clearance of psoriasis (12 months after starting UC-MSCs infusion). (B) Patient no. 2: (B1) Pre the first UC-MSCs infusion: drip-like plaques with adherent silvery scales distributed extensively, mainly on extensor aspects of elbows and knees, back, lumbosacral region, and around the umbilicus; (B2) After the third UC-MSCs infusion, the patient's skin turned smooth without any active lesions (the pigmentation was due to the historical steroidal agent). UC-MSCs = umbilical cord-derived mesenchymal stem cells.

^bCell and Gene Therapy Center
Affiliated Hospital of Academy of Military Medical Sciences
Beijing, China

^cDepartment of Pathology
Affiliated Hospital of Academy of Military Medical Sciences
Beijing, China

^dDepartment of Dermatology
Affiliated Hospital of Academy of Military Medical Sciences
Beijing, China

<http://dx.doi.org/10.1016/j.amjmed.2015.11.001>

References

1. Menter A, Griffiths CE. Current and future management of psoriasis. *Lancet*. 2007;370(9583):272-284.
2. Zhao Q, Ren H, Han Z, et al. Mesenchymal stem cells: immunomodulatory capability and clinical potential in immune diseases. *J Cell Immunother*. 2015. (in press). Available at: <http://dx.doi.org/10.1016/j.jocit.2014.12.001>. Accessed November 16, 2015.
3. Jaganathan B, Tisato V, Vulliamy T, et al. Effects of MSC co-injection on the reconstitution of aplastic anemia patient following hematopoietic stem cell transplantation. *Leukemia*. 2010;24(10):1791-1795.
4. Wang Y, Chen X, Cao W, Shi Y. Plasticity of mesenchymal stem cells in immunomodulation: pathological and therapeutic implications. *Nat Immunol*. 2014;15(11):1009-1016.
5. Hinterberger W, Hinterberger-Fischer M, Marmont A. Clinically demonstrable anti-autoimmunity mediated by allogeneic immune cells favorably affects outcome after stem cell transplantation in human autoimmune diseases. *Bone Marrow Transplant*. 2002;30(11):753-759.