


## ORIGINAL ARTICLE

# Efficacy of combined treatment with human adipose tissue stem cell-derived exosome-containing solution and microneedling for facial skin aging: A 12-week prospective, randomized, split-face study

Gyeong-Hun Park MD, PhD<sup>1</sup> | Hyuck Hoon Kwon MD, PhD<sup>2</sup>  | Joon Seok MD, PhD<sup>3</sup> | Steven Hoseong Yang MD, PhD<sup>4</sup> | Joon Lee MD, MS<sup>5</sup> | Byung Chul Park MD, PhD<sup>6</sup> | Eun Shin MD, PhD<sup>7</sup> | Kui Young Park MD, PhD<sup>3</sup>

<sup>1</sup>Department of Dermatology, Dongtan Sacred Heart Hospital, Hallym University College of Medicine, Hwaseong, Republic of Korea

<sup>2</sup>Gangdong Oaro Dermatology Institute, Seoul, Republic of Korea

<sup>3</sup>Department of Dermatology, Chung-Ang University, College of Medicine, Seoul, Republic of Korea

<sup>4</sup>Guam Dermatology Institute, Guam, USA

<sup>5</sup>Yongsan Oaro Dermatology Institute, Seoul, Republic of Korea

<sup>6</sup>Department of Dermatology, Dankook University, College of Medicine, Cheonan, Republic of Korea

<sup>7</sup>Department of Pathology, Dongtan Sacred Heart Hospital, Hallym University College of Medicine, Hwaseong, Republic of Korea

## Correspondence

Kui Young Park, MD, PhD. Department of Dermatology, Chung-Ang University, College of Medicine, 102, Heukseok-ro, Dongjak-gu, Seoul 06973, Republic of Korea.  
Email: [kyky@cau.ac.kr](mailto:kyky@cau.ac.kr)

## Funding information

This work was supported by the National Research Foundation of Korea (NRF) grant funded by the Korea government (MSIT) (No. 2022R1A2C2091741).

## Abstract

**Background:** Studies have reported promising results of mesenchymal stem cell therapies for skin aging. However, in the use of mesenchymal stem cells, some drawbacks including rarely possible tumorigenicity and low engraftment rates have limited their widespread clinical use. Adipose tissue stem cell-derived exosomes (ASCEs) are emerging as effective cell-free therapeutic agents.

**Aims:** It was evaluated the clinical efficacy of combining the application of human ASCE-containing solution (HACS) with microneedling to treat facial skin aging.

**Methods:** A 12-week, prospective, randomized, split-face, comparative study was conducted. Twenty-eight individuals underwent three treatment sessions separated by 3-week intervals and were followed up for 6 weeks after the last session. At each treatment session, HACS and microneedling were administered to one side of the face, and normal saline solution and microneedling were administered to the other side as a control.

**Results:** The Global Aesthetic Improvement Scale score was significantly higher on the HACS-treated side than on the control side at the final follow-up visit ( $p=0.005$ ).

Gyeong-Hun Park and Hyuck Hoon Kwon contributed equally to this work as first authors.

Abbreviation: ASCEs, adipose tissue stem cell-derived exosomes; EMLA, eutectic mixture of local anesthetics; GAIS, Global Aesthetic Improvement Scale; HACS, human adipose tissue stem cell-derived exosome-containing solution; MMPs, matrix metalloproteinases; NRF2, nuclear factor erythroid 2-related factor 2; PRDXs, peroxiredoxins; Ra, the average roughness; Rt, the maximum height of the roughness profile; Rz, the average maximum height of the roughness; SRLV, Skin Rejuvenation Lyophilized Vial

This is an open access article under the terms of the [Creative Commons Attribution](https://creativecommons.org/licenses/by/4.0/) License, which permits use, distribution and reproduction in any medium, provided the original work is properly cited.

© 2023 The Authors. *Journal of Cosmetic Dermatology* published by Wiley Periodicals LLC.

Objective measurements obtained by different devices including PRIMOS Premium, Cutometer MPA 580, Corneometer CM 825, and Mark-Vu confirmed greater clinical improvements in skin wrinkles, elasticity, hydration, and pigmentation on the HACS-treated side than on the control side. The results of the histopathological evaluation were consistent with the clinical findings. No serious adverse events were observed.

**Conclusions:** These findings demonstrate that combined treatment using HACS and microneedling is effective and safe for treating facial skin aging.

#### KEYWORDS

adipose-derived stem cells, aging, exosome, microneedle

## 1 | INTRODUCTION

Facial skin aging causes gradual changes in appearance that can lead to cosmetic concerns and psychosocial distress.<sup>1</sup> Skin aging is a complex phenomenon induced by extrinsic and intrinsic processes. The former results from external stimuli, including photodamage due to ultraviolet exposure, and the latter proceeds with time and is determined by the genetic background. Both processes lead to various skin changes, including irregular pigmentation, wrinkle formation, dryness, skin thinning, laxity, and elastosis.<sup>1</sup>

Various treatments have been used to delay the apparition of the abovementioned epidermal and dermal changes induced by skin aging. In particular, recent studies have reported promising results of using stem cell therapies with mesenchymal and adipose-derived stem cells for skin aging.<sup>2</sup> Mesenchymal stem cells have self-renewal capacity and the ability to differentiate into various cell types and offer great potential applications in various diseases and regenerative medicine. Adipose-derived stem cells, a type of mesenchymal stem cells from the adipose tissue, have clear advantages over other stem cells in terms of accessibility and abundance; thus, their potential clinical applications have been actively investigated.<sup>3</sup> Adipose-derived stem cells have been shown to be effective in treating cutaneous aging through in vivo and in vitro studies.<sup>2</sup> Paracrine signaling seems to play an important role in the anti-aging effects of adipose-derived stem cells.<sup>2</sup> However, the widespread clinical use of adipose-derived stem cells has been limited owing to rarely possible tumorigenicity reported in some studies, a low engraftment rate, and difficulty in quality control.<sup>4</sup>

Exosomes are spherical extracellular vesicles with a lipid bilayer and a diameter of approximately 30–200 nm. Recently, these have been reported to critically mediate intercellular communication by transferring proteins and genetic material from one cell to another. Mesenchymal stem cells release exosomes that can mediate paracrine signaling to target cells. Mesenchymal stem cell-derived exosomes have been shown to keep the biological activities of mesenchymal stem cells, indicating that using these exosomes can serve as a replacement treatment for whole-cell therapy with mesenchymal stem cells.<sup>5</sup> Moreover, recent studies have shown that the therapeutic effects of adipose-derived stem

cells are mediated by adipose tissue stem cell-derived exosomes (ASCEs).<sup>6</sup> Accordingly, ASCEs are emerging as safe, effective, and cell-free therapeutic agents that can overcome the limitations of stem cell therapy.<sup>5,6</sup>

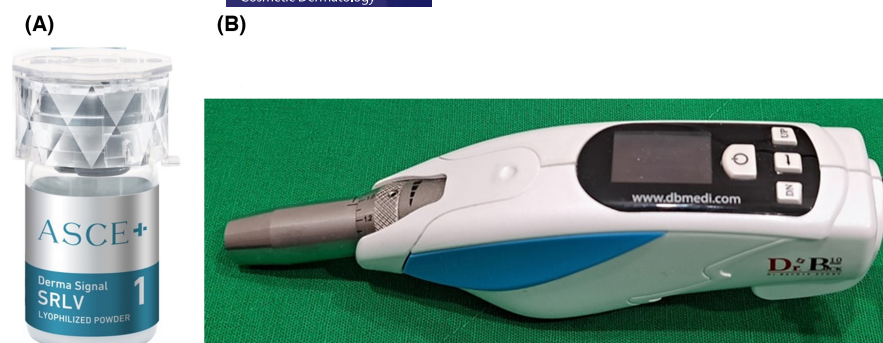Based on the anti-aging effect of adipose-derived stem cells and the biological activities of exosomes,<sup>2,5,6</sup> it was hypothesized that the use of ASCEs could be a safe and effective treatment method for facial skin aging. Hence, this study aimed to examine the effect of using human ASCE-containing solution (HACS) and microneedling on facial skin aging in terms of wrinkles, elasticity, hydration, and pigmentation in a randomized, split-face clinical study.

## 2 | MATERIALS AND METHODS

### 2.1 | Study design

A 12-week prospective, randomized, split-face comparative study was performed to assess the clinical efficacy of combining the application of HACS with microneedling to treat facial skin aging. The study was approved by the Institutional Review Board and was conducted in accordance with the Declaration of Helsinki. All study participants provided informed consent before enrolment. The individuals underwent three treatment sessions every 3 weeks and were followed up for 6 weeks after the last intervention. At each treatment session, HACS and microneedling were administered to one side of the face and normal saline solution and microneedling were administered to the other side as a control. The agent applied to each half face was randomly allocated using block randomization with block size of four.

Twenty-eight subjects with facial skin aging were enrolled in this study. As prior data for power analysis were not available, the sample size was determined based on feasibility. Individuals aged  $\geq 40$  years were eligible for inclusion in the study. The exclusion criteria included pregnancy, history of keloid scarring, and acute inflammatory or infectious conditions on the face. In addition, the concurrent use of treatments that may affect the evaluation of effects, such as chemical and mechanical resurfacing, photorejuvenation, and filler injection, was prohibited during the study period.



**FIGURE 1** (A) ASCE+ Derma Signal Skin Rejuvenation Lyophilized Vial (SRLV)-S (ExoCoBio Inc., Seoul, Republic of Korea), and (B) the microneedling device (Dr. Back 10 Story FN-1, Dongbang Medi-care, Seongnam, Republic of Korea).

**TABLE 1** Composition of the human adipose tissue stem cell-derived exosome-containing solution.

Composition	Percent	Remark
Water	84.7	Solvent
Human adipocyte conditioned media extract	12.5	ASCEs ( $5 \times 10^9$ particles)
Peptide complex	0.0006	Skin conditioning agent
Amino acids	1.0	Skin conditioning agent
Potassium chloride and others	1.7	Skin conditioning agent

Abbreviation: ASCEs, adipose tissue stem cell-derived exosomes.

## 2.2 | Treatment protocol

Each participant washed their entire face with mild soap, and 30 min before treatment, eutectic mixture of local anesthetics (EMLA®) cream (AstraZeneca) was applied with occlusion for topical anesthesia. Next, 2 mL normal saline solution was mixed with a vial of ASCE+ Derma Signal Skin Rejuvenation Lyophilized Vial (SRLV)-S (ExoCoBio Inc. [Figure 1A](#)) to prepare a HACS. The HACS was topically applied to the one-half face, followed by microneedling at a depth of 1 mm (Dr. Back 10 Story FN-1, Dongbang Medi-care, [Figure 1B](#)). The composition of HACS is summarized in [Table 1](#). The other half face was treated with 2 mL normal saline solution followed by microneedling.

## 2.3 | Clinical evaluation

At each visit, all participants were photographed using a standardized digital camera (EOS 600D, Canon) under the same lighting conditions, and the overall improvement in facial skin aging was assessed using the Global Aesthetic Improvement Scale (GAIS) at Weeks 3, 6, and 12.<sup>7</sup> Two board-certified dermatologists determined the GAIS score by analyzing the photographs and assigning them a number on a 5-point grading scale depending on the degree of improvement (grade 1 = worsened, 2 = unchanged, 3 = improved, 4 = much improved, and 5 = very much improved).

Furthermore, the participants were asked to report adverse events including erythema, edema, petechiae, and scarring at each visit, and a physical examination was performed for safety concerns.

## 2.4 | Instrumental evaluation

Noninvasive devices were used to evaluate the treatment efficacy objectively. Skin wrinkles were assessed using a non-contact, high-resolution, optical, three-dimensional skin-measuring device (PRIMOS Premium, Canfield Scientific) that measures the surface roughness of the skin. The following parameters were analyzed to assess skin wrinkles: average roughness (Ra), the maximum height of the roughness profile (Rt), and an average maximum height of the roughness (Rz). Skin elasticity was evaluated using the Cutometer MPA 580 (Courage + Khazaka). Biological elasticity (R7), which is calculated as the ratio of elastic recovery to total deformation, was the parameter analyzed to assess skin elasticity. Skin hydration was measured using Corneometer CM 825 (Courage + Khazaka). A skin diagnostic imaging system (Mark-Vu, PSI PLUS Co., Ltd.) was used to assess skin pigmentation, which is based on the analysis of images under ultraviolet light to determine a melanin index.<sup>8,9</sup>

## 2.5 | Histopathologic evaluation

Skin biopsies were obtained from four participants using a 2 mm punch at baseline and follow-up visits. The specimens were stained with hematoxylin and eosin, Masson trichrome, Herovici, Verhoeff-van Gieson, and colloidal iron.<sup>10</sup> A board-certified pathologist independently evaluated the histopathological characteristics of the tissue sections by performing a standard microscopic examination.

## 2.6 | Statistical analysis

Descriptive statistics were presented as mean  $\pm$  standard deviation or proportion for the baseline data. The GAIS score was analyzed using a cumulative link mixed model, which used a logit link function and included fixed factors of treatment (HACS versus control), time

(Weeks 3, 6, and 12), and their interaction and a random intercept for each participant. In addition, linear mixed effect models were used to analyze wrinkles, elasticity, hydration, and pigmentation of the skin, and mean percent changes from baseline were modeled with treatment, time, and their interaction as fixed factors and a random intercept at the participant level. A  $p$  value  $<0.05$  was considered statistically significant. All statistical analyses were performed using R, version 4.1.1 (R Foundation for Statistical Computing).

### 3 | RESULTS

A total of 28 individuals participated in this study, and all of them completed the study. The demographic and baseline clinical characteristics of the participants are summarized in Table 2.

#### 3.1 | Clinical evaluation of overall improvement

During the study period, the GAIS score gradually increased on both facial sides: on the one treated with microneedling combined with HACS (HACS side) and on the other treated with microneedling combined with normal saline solution (control side) (Figure 2). However, overall improvement in facial skin aging was more prominent on the HACS side than on the control side. The

difference between the two treatments was not significant at Week 3 ( $p=0.202$ ), but it became statistically significant at Week 6 ( $p=0.023$ ). At the final follow-up visit (Week 12), 13 cases (46%) had a GAIS score of 3, 4 cases (14%) scored 4, and 4 cases (14%) scored 5 for the HACS side; whereas 13 cases (46%) scored 3, 2 cases (7%) scored 4, and 2 cases (7%) scored 5 for the control side. These results indicate that the HACS side exhibited a significantly greater improvement in facial skin aging than the control side at the final follow-up visit ( $p=0.005$ ). Figure 3 shows the photographs taken at baseline and follow-up visits for representative cases.

#### 3.2 | Improvement in skin wrinkles

Skin wrinkles improved on both sides compared to those at baseline, but the therapeutic effect on the HACS side was significantly greater than that on the control side (Figure 4). At the final follow-up visit, the mean percent reductions in Ra, Rt, and Rz were 12.4, 14.4, and 13.4%, respectively, on the HACS side. In contrast, these were 6.6, 6.8, and 7.1%, respectively, on the control side, showing statistically significant differences between the two regimens ( $p=0.031$ , 0.008, and 0.007, respectively). All three parameters consistently revealed that the application of HACS was effective in treating skin wrinkles.

#### 3.3 | Improvement in skin elasticity

A significant increase in skin elasticity was observed on the HACS side at every assessment point compared to that at baseline. In contrast, skin elasticity did not significantly improve on the control side during the study (Figure 5A). At Week 12, skin elasticity increased by an average of 11.3% from baseline on the HACS side but decreased by 3.3% on the control side. This revealed a statistically significant difference between the two sides ( $p=0.002$ ).

#### 3.4 | Improvement in skin hydration

Both treatments significantly increased skin hydration throughout the treatment period compared to that at baseline (Figure 5B). In particular, skin hydration on the HACS side continued to increase until Week 12, with an average increase of 6.5% at the last follow-up visit. This was significantly greater than the increase of 4.5% observed on the control side at Week 12 ( $p=0.037$ ).

#### 3.5 | Improvement in skin pigmentation

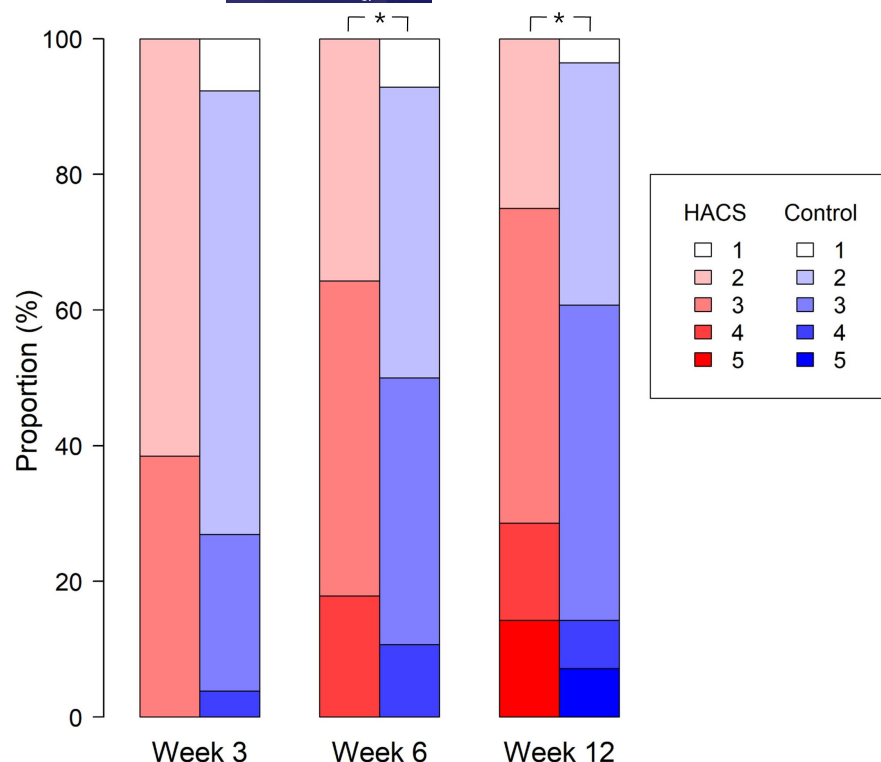
There was no significant change in the melanin index on the control side during the study period. In contrast, the melanin index significantly decreased on the HACS side from baseline to Week 12 (Figure 6). At the final follow-up evaluation, the average decrease

TABLE 2 Demographic and baseline characteristics of participants.

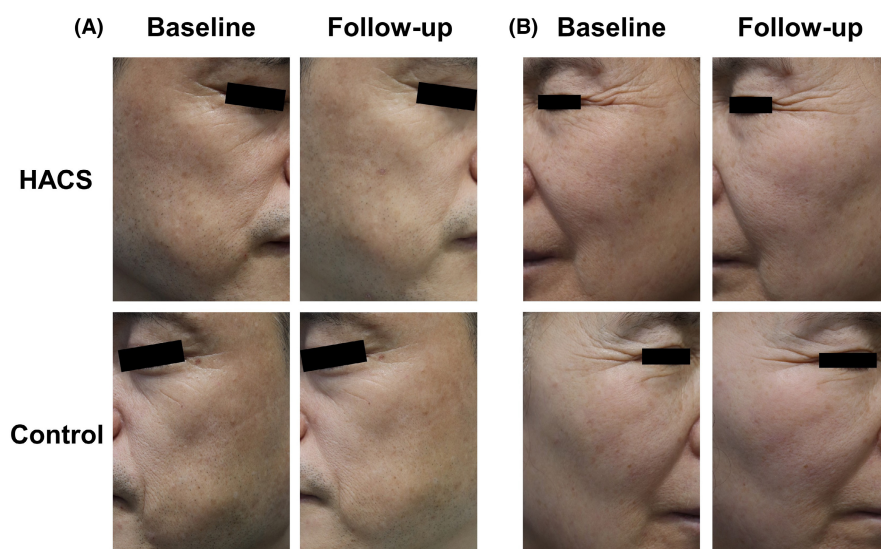
	HACS side	Control side
Age (year)	54.0 ± 7.8 (43–66)	
Sex		
Male	8 (28.6%)	
Female	20 (71.4%)	
Fitzpatrick skin type		
Type III	12 (42.9%)	
Type IV	16 (57.1%)	
Skin wrinkles		
Ra	18.4 ± 4.3 (12.8–28.9)	16.4 ± 3.8 (11.0–25.9)
Rt	147.7 ± 35.7 (96.0–227.3)	137.6 ± 34.5 (103.0–209.5)
Rz	94.7 ± 20.6 (67.1–149.6)	84.8 ± 17.9 (59.0–126.0)
Skin elasticity	0.229 ± 0.051 (0.151–0.351)	0.259 ± 0.056 (0.158–0.363)
Skin hydration	57.0 ± 10.8 (36.0–78.3)	57.7 ± 9.4 (43.3–77.3)
Melanin index	33.6 ± 14.2 (12.0–72.0)	32.5 ± 14.3 (13.0–72.0)

Note: Mean ± SD (range) for continuous variables; N (%) for categorical variables.

Abbreviations: HACS, human adipose tissue stem cell-derived exosome-containing solution; Ra, the average roughness; Rt, the maximum height of the roughness profile; Rz, the average maximum height of the roughness.



**FIGURE 2** GAIS scores for skin aging on the HACS and control sides at each post-treatment visit. \* $p < 0.05$  between the two sides. GAIS: Global Aesthetic Improvement Scale (grade 1 = worsened, 2 = unchanged, 3 = improved, 4 = much improved, and 5 = very much improved); HACS: human adipose tissue stem cell-derived exosome-containing solution.



**FIGURE 3** Baseline and follow-up photographs of the HACS and control sides in (A) a 52-year-old male (GAIS scores of 5 and 3, respectively) and (B) a 60-year-old female (GAIS scores of 5 and 4, respectively). HACS: human adipose tissue stem cell-derived exosome-containing solution; GAIS: Global Aesthetic Improvement Scale.

in the melanin index was 9.9% on the HACS side and 1.0% on the control side, showing a statistically significant difference between the two sides ( $p = 0.044$ ).

### 3.6 | Histopathologic evaluation

Histological specimens obtained from the HACS side at the final follow-up visit showed a greater density of collagen and elastic fibers and increased deposition of mucin and newly synthesized collagen compared to those at baseline (Figure 7). Similar patterns of histological changes were observed on the control side, but these were less pronounced than those on the HACS side.

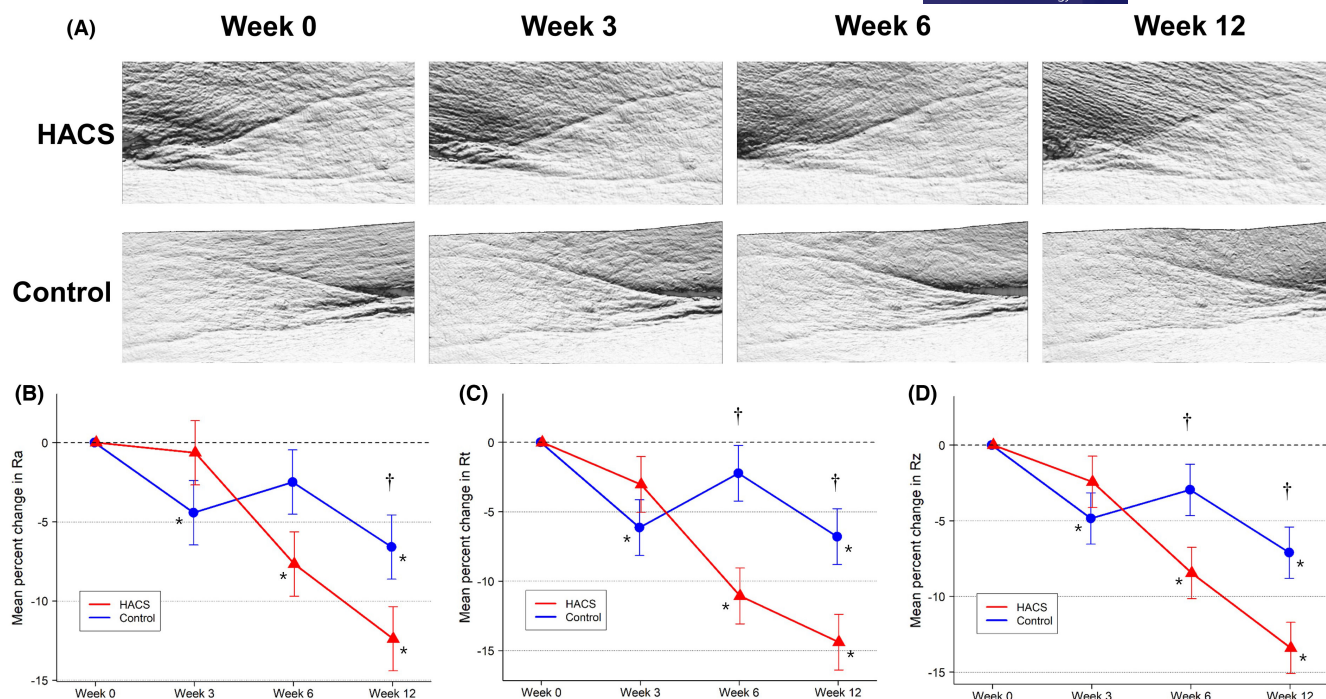
### 3.7 | Adverse events

No serious adverse events were observed during the study. Transient erythema, edema, and petechiae were observed during and after the treatment. However, these were mild symptoms and resolved spontaneously within 1 week. No permanent skin changes or scar formation was observed in any participant.

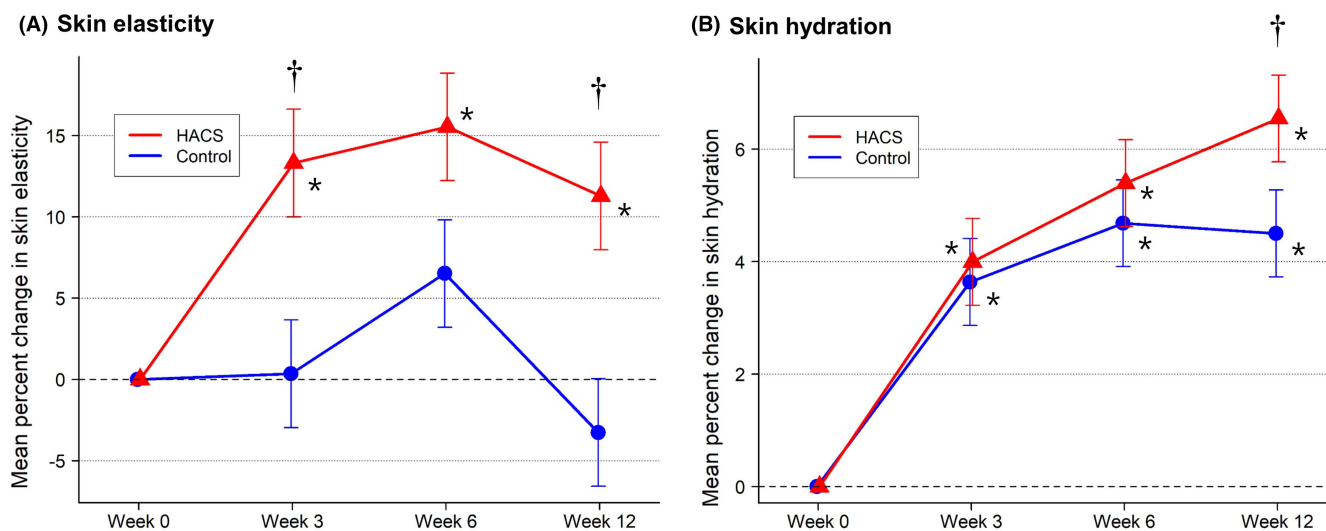
## 4 | DISCUSSION

This study demonstrated that combined treatment with HACS application and microneedling is effective for facial skin aging. Based





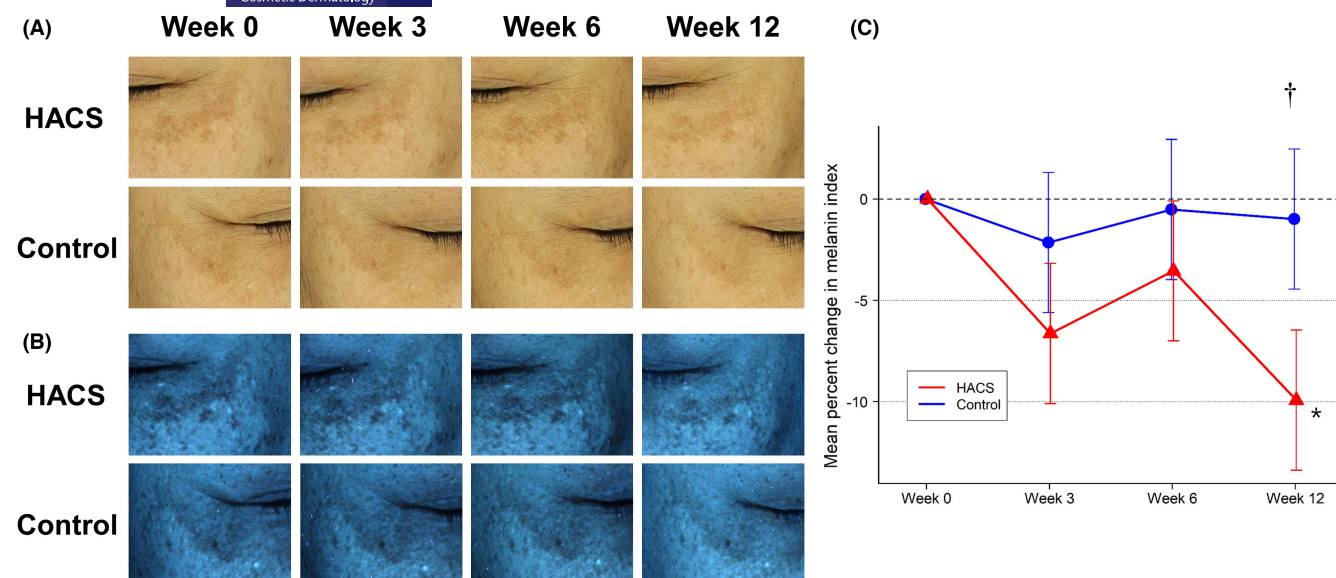
**FIGURE 4** Evaluation of skin wrinkles using a high-resolution, optical, three-dimensional, in vivo skin-measuring device. (A) Three-dimensional images for skin wrinkles on the HACS and control sides in a 47-year-old male. Mean percent changes in (B) the average roughness (Ra), (C) the maximum height of the roughness profile (Rt), and (D) the average maximum height of the roughness (Rz) on the HACS and control sides. \* $p < 0.05$  compared with baseline; † $p < 0.05$  between the two sides. The error bars indicate standard errors. HACS: human adipose tissue stem cell-derived exosome-containing solution.



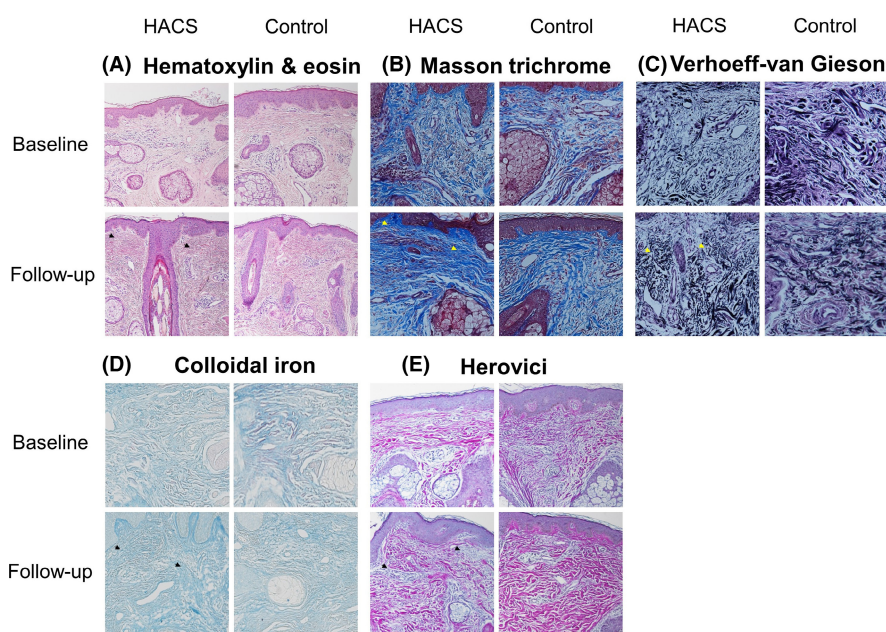
**FIGURE 5** Evaluation of skin elasticity and hydration based on instrumental measurements. Mean percent changes in (A) biological elasticity and (B) skin hydration on the HACS and control sides at each post-treatment visit. \* $p < 0.05$  compared with baseline; † $p < 0.05$  between the two sides. The error bars indicate standard errors. HACS: human adipose tissue stem cell-derived exosome-containing solution.

on the results obtained from clinical evaluation, objective measurement of various skin aging signs, and microscopic evaluation of histological changes, this combined therapy exhibited higher efficacy than that of microneedling alone. Furthermore, combining both methods was a safe treatment with tolerable side effect profiles.

The molecular mechanisms that underlie aging have not yet been fully elucidated; however, it is widely accepted that the cumulative damage caused by free radicals, including reactive oxygen species, plays an important role in that process. During skin aging, oxidative stress activates transcription factors such as nuclear factor  $\kappa$ B, which induces the expression of pro-inflammatory cytokines to increase



**FIGURE 6** Evaluation of skin pigmentation using a skin diagnostic imaging system. Digital photographs of the HACS and control sides in a 48-year-old female under (A) normal and (B) ultraviolet light. (C) Mean percent changes in melanin index on the HACS and control sides at each post-treatment visit. \* $p < 0.05$  compared with baseline; † $p < 0.05$  between the two sides. The error bars indicate standard errors. HACS: human adipose tissue stem cell-derived exosome-containing solution.



**FIGURE 7** Histopathological changes in facial skin tissues from the HACS and control sides between baseline and follow-up visits (original magnification  $\times 100$ ). The arrows indicate a greater density of collagen (A,B) and elastic fibers (C) and increased deposition of mucin (D) and newly synthesized collagen (E). HACS: human adipose tissue stem cell-derived exosome-containing solution.

the secretion of matrix metalloproteinases (MMPs). Oxidative stress also activates the transcription factor activator protein 1, which increases the expression of MMPs and decreases the expression of transforming growth factor- $\beta$ .<sup>11</sup> Consequently, collagen degradation is increased and collagen synthesis is reduced, contributing to skin aging. In addition, oxidative stress can disrupt the normal loop structure of telomeres and expose TTAGGG tandem repeats, leading to the activation of p53, which induces proliferative senescence or apoptosis.<sup>12</sup>

ASCEs can effectively inhibit the key processes of skin aging. Consistent with the antioxidant properties of mesenchymal stem cell-derived exosomes in various organ systems, it has been reported

that ASCEs decrease oxidative stress by reducing the production of reactive oxygen species.<sup>13</sup> Extracellular vesicles produced by mesenchymal stem cells were highly enriched for antioxidant enzymes peroxiredoxins (PRDXs),<sup>14</sup> and ASCEs contain PRDXs such as PRDX1, PRDX4, and PRDX6.<sup>15</sup> ASCEs also attenuate ultraviolet-induced apoptosis of the target cells,<sup>13</sup> and suppress the nuclear factor  $\kappa$ B pathway, downregulating the expression of pro-inflammatory cytokines such as interleukin-13, interleukin-6, interleukin-4, interleukin-1 $\beta$ , tumor necrosis factor- $\alpha$ , and interferon- $\gamma$ .<sup>15-17</sup> In addition, ASCEs were reported to increase the expression of transforming growth factor- $\beta$  and decrease the expression of MMPs, including MMP-1 and MMP-3.<sup>18,19</sup> As a result, ASCEs promote fibroblast

proliferation and collagen synthesis, accelerate extracellular matrix remodeling, and increase dermal thickness.<sup>19</sup> These key functions of ASCs may have contributed to the improvement in skin wrinkles and elasticity that were observed in the present study.

The epidermal barrier becomes more fragile during skin aging, and its recovery after disruption is delayed. The levels of major lipid species, including ceramides, tend to decrease in the stratum corneum with age, resulting in a marked reduction in secreted lamellar body contents. This reduction in the lipid content of the stratum corneum, particularly the ceramide deficiency, appears to explain the impaired barrier function. Thus, the restoration of ceramide levels could improve the altered barrier function in aged skin.<sup>20</sup> In addition, ASCs have been reported to induce the expression of genes related to the skin barrier and lipid metabolism. In particular, ASCs induce the de novo synthesis of ceramides in the skin, promoting the formation of epidermal lamellar bodies and lamellar layers.<sup>15</sup> Consequently, the action of these exosomes reduces trans-epidermal water loss, improves stratum corneum hydration, and restores epidermal barrier function.<sup>15</sup> Therefore, the improvement in skin hydration observed in this study may have been attributed to the role of ASCs.

Skin aging, particularly photoaging, results in mottled pigmentation and solar lentigines. These processes seem to be mediated by the crosstalk between various types of cells, including keratinocytes, melanocytes, fibroblasts, and endothelial cells.<sup>21</sup> A recent study reported that altered signaling of the nuclear factor erythroid 2-related factor 2 (NRF2) might be responsible for ultraviolet-induced skin pigmentation.<sup>22</sup> NRF2 signaling reduces oxidative stress by regulating antioxidant and detoxifying enzyme levels.<sup>21</sup> Lentigines and photodamaged skin exhibits a reduced expression of NRF2, and an NRF2 agonist improves mottled hyperpigmentation in the photodamaged skin.<sup>22</sup> These findings indicate that enhancing the NRF2 signaling pathway could be a promising therapeutic strategy for skin aging. Considering that ASCs have been reported to upregulate the expression of NRF2 and enhance the nuclear translocation of NRF2,<sup>23</sup> these could be useful therapeutic agents to treat pigmentation in photoaged skin.

In this study, microneedling was used to facilitate ASC penetration into the dermis. Microneedling effectively enables transdermal drug delivery by creating channels through the skin. Many studies have shown that microneedling can be used as a drug delivery method to deliver both large molecules and small-sized drugs.<sup>24</sup> In addition, microneedling induces collagen synthesis, thereby enhancing skin-rejuvenating effects.<sup>25</sup> This technique produces controlled skin injury by creating microchannels with minimal epidermal damage. Furthermore, it stimulates the wound-healing process in the dermal layer, which induces neovascularization and neocollagenesis by upregulating the expression of various growth factors, including vascular endothelial growth factor, platelet-derived growth factor, fibroblast growth factor, and transforming growth factor- $\beta$ . As a result, microneedling leads to increased collagen and elastic fiber deposition, which is clinically evidenced as skin tightening and wrinkle reduction.<sup>25</sup> These rejuvenating effects of microneedling may have acted synergistically with those of ASCs in the present study.

This study had several limitations. All participants were of the same ethnicity, and the number of participants was relatively small. The follow up period was rather short. Results of a longer follow-up period and larger numbers of subjects would provide more useful clinical information.

This study also had several strengths. To the best of our knowledge, this is the first human clinical study to use ASCs for facial skin aging. Another strength of this study is its randomized split-face design that prevents the effects of possible confounding factors.

In conclusion, this study demonstrated the efficacy and safety of HACS application along with microneedling for the treatment of facial skin aging. In addition, the combination of these therapies provided synergistic effects for the rejuvenation of the facial skin. However, a large-scale, long-term clinical study involving diverse ethnic groups of patients is required to generalize these findings to other populations.

## AUTHOR CONTRIBUTIONS

Hyuck Hoon Kwon and Kui Young Park conceived and designed the study. Gyeong-Hun Park, Eun Shin, Joon Seok, and Kui Young Park collected the data. Gyeong-Hun Park, Steven Hoseong Yang, Joon Lee, and Byung Chul Park contributed to analysis and interpretation of data. Gyeong-Hun Park and Hyuck Hoon Kwon wrote the paper. All authors approved the final manuscript.

## ACKNOWLEDGMENTS

This work was supported by the National Research Foundation of Korea (NRF) grant funded by the Korea government (MSIT) (No. 2022R1A2C2091741).

## CONFLICT OF INTEREST STATEMENT

None declared.

## DATA AVAILABILITY STATEMENT

Research data are not shared.

## ETHICS STATEMENT

The authors comply with the research ethics regulations of the Journal of Cosmetic Dermatology.

## ORCID

Hyuck Hoon Kwon  <https://orcid.org/0000-0001-8194-1790>

## REFERENCES

1. Chung JH, Hanft VN, Kang S. Aging and photoaging. *J Am Acad Dermatol*. 2003;49:690-697.
2. Zarei F, Abbaszadeh A. Application of cell therapy for anti-aging facial skin. *Curr Stem Cell Res Ther*. 2019;14:244-248.
3. Zuk PA. The adipose-derived stem cell: looking back and looking ahead. *Mol Biol Cell*. 2010;21:1783-1787.
4. Wang Y, Han ZB, Song YP, Han ZC. Safety of mesenchymal stem cells for clinical application. *Stem Cells Int*. 2012;2012:652034.
5. Casado-Diaz A, Quesada-Gomez JM, Dorado G. Extracellular vesicles derived from mesenchymal stem cells (MSC) in regenerative medicine: applications in skin wound healing. *Front Bioeng Biotechnol*. 2020;8:146.



6. Mizuta Y, Akahoshi T, Guo J, et al. Exosomes from adipose tissue-derived mesenchymal stem cells ameliorate histone-induced acute lung injury by activating the PI3K/Akt pathway in endothelial cells. *Stem Cell Res Ther*. 2020;11:508.
7. de Oliveira TC, Rocha SF, Ramos DG, Ramos CG, Carvalho MV, Ramos MG. Effects of multipolar radiofrequency and pulsed electromagnetic field treatment for face and neck rejuvenation. *Dermatol Res Pract*. 2017;2017:4146391.
8. Ryu JH, Seo YK, Boo YC, Chang MY, Kwak TJ, Koh JS. A quantitative evaluation method of skin texture affected by skin ageing using replica images of the cheek. *Int J Cosmet Sci*. 2014;36:247-252.
9. Lee YI, Kim S, Kim J, Kim J, Chung KB, Lee JH. Randomized controlled study for the anti-aging effect of human adipocyte-derived mesenchymal stem cell media combined with niacinamide after laser therapy. *J Cosmet Dermatol*. 2021;20:1774-1781.
10. Kwon HH, Yang SH, Cho YJ, et al. Comparison of a 1064-nm neodymium-doped yttrium aluminum garnet picosecond laser using a diffractive optical element vs. a nonablative 1550-nm erbium-glass laser for the treatment of facial acne scarring in Asian patients: a 17-week prospective, randomized, split-face, controlled trial. *J Eur Acad Dermatol Venereol*. 2020;34:2907-2913.
11. Shin JW, Kwon SH, Choi JY, et al. Molecular mechanisms of dermal aging and antiaging approaches. *Int J Mol Sci*. 2019;20:2126-2141.
12. Gilchrist BA. Using DNA damage responses to prevent and treat skin cancers. *J Dermatol*. 2004;31:862-877.
13. Hong Y, Sun Y, Rong X, Li D, Lu Y, Ji Y. Exosomes from adipose-derived stem cells attenuate UVB-induced apoptosis, ROS, and the Ca<sup>2+</sup> level in HLEC cells. *Exp Cell Res*. 2020;396:112321.
14. Liu S, Mahairaki V, Bai H, et al. Highly purified human extracellular vesicles produced by stem cells alleviate aging cellular phenotypes of senescent human cells. *Stem Cells*. 2019;37:779-790.
15. Shin KO, Ha DH, Kim JO, et al. Exosomes from human adipose tissue-derived mesenchymal stem cells promote epidermal barrier repair by inducing de novo synthesis of ceramides in atopic dermatitis. *Cell*. 2020;9:680.
16. Feng N, Jia Y, Huang X. Exosomes from adipose-derived stem cells alleviate neural injury caused by microglia activation via suppressing NF- $\kappa$ B and MAPK pathway. *J Neuroimmunol*. 2019;334:576996.
17. Xiong M, Zhang Q, Hu W, et al. Exosomes from adipose-derived stem cells: the emerging roles and applications in tissue regeneration of plastic and cosmetic surgery. *Front Cell Dev Biol*. 2020;8:574223.
18. Heidari N, Abbasi-Kenarsari H, Namaki S, et al. Adipose-derived mesenchymal stem cell-secreted exosome alleviates dextran sulfate sodium-induced acute colitis by Treg cell induction and inflammatory cytokine reduction. *J Cell Physiol*. 2021;236:5906-5920.
19. Liang JX, Liao X, Li SH, et al. Antiaging properties of exosomes from adipose-derived mesenchymal stem cells in Photoaged rat skin. *Biomed Res Int*. 2020;2020:6406395.
20. Jonca N. Ceramides metabolism and impaired epidermal barrier in cutaneous diseases and skin aging: focus on the role of the enzyme PNPLA1 in the synthesis of w-O-acylceramides and its pathophysiological involvement in some forms of congenital ichthyoses. *OCL*. 2019;26:17.
21. Kang HY, Lee JW, Papaccio F, Bellei B, Picardo M. Alterations of the pigmentation system in the aging process. *Pigment Cell Melanoma Res*. 2021;34:800-813.
22. Kerns ML, Miller RJ, Mazhar M, et al. Pathogenic and therapeutic role for NRF2 signaling in ultraviolet light-induced skin pigmentation. *JCI Insight*. 2020;5:e139342.
23. Shen K, Jia Y, Wang X, et al. Exosomes from adipose-derived stem cells alleviate the inflammation and oxidative stress via regulating Nrf2/HO-1 axis in macrophages. *Free Radic Biol Med*. 2021;165:54-66.
24. Parhi R, Supriya ND. Review of microneedle based transdermal drug delivery systems. *Int J Pharm Sci Nanotechnol*. 2019;12:4511-4523.
25. Alster TS, Graham PM. Microneedling: a review and practical guide. *Dermatol Surg*. 2018;44:397-404.

**How to cite this article:** Park G-H, Kwon HH, Seok J, et al. Efficacy of combined treatment with human adipose tissue stem cell-derived exosome-containing solution and microneedling for facial skin aging: A 12-week prospective, randomized, split-face study. *J Cosmet Dermatol*. 2023;22:3418-3426. doi:[10.1111/jocd.15872](https://doi.org/10.1111/jocd.15872)