




Contents lists available at ScienceDirect

Heliyon

journal homepage: [www.cell.com/heliyon](http://www.cell.com/heliyon)



Research article



# Effect of adipose mesenchymal stem cell-derived exosomes on allergic rhinitis in mice

Xiaojie Xu, Chang Li, Qin Qin, Feiyan Han, Ying Wang<sup>\*</sup>

Nasal Department, the First Affiliated Hospital of Zhengzhou University, Zhengzhou, 450052, China

## ARTICLE INFO

### Keywords:

Adipose mesenchymal stem cell-derived exosomes  
Exosomes  
Immunoregulation  
Allergic rhinitis  
IL-4  
IL-5  
IFN- $\gamma$   
Ig-E  
Goblet cells  
Eosinophils

## ABSTRACT

**Background:** At present, the treatment for allergic rhinitis (AR) is only limited to symptom relief, and AR is not able to be cured. It is important to find new therapeutic regimens for AR.

**Objective:** To explore the effect of adipose mesenchymal stem cell-derived exosomes (AMSC-exos) on AR in mice.

**Methods:** Primary human AMSCs were cultured up to fourth or fifth passage AMSCs which were used to extract AMSC-exos by ultracentrifugation. The AMSC-exos were identified in size, morphology and surface marker proteins. AR mouse models were made, and then effects of the AMSC-exos on AR mouse models were observed by injection of AMSC-exos into their tail veins. A total of 21 mice were divided into normal mice with injection of phosphate buffered saline (PBS) group (Normal + PBS group, 7 mice), AR mice with injection of AMSC-exos group (AR + AMSC-exos group, 7 mice) and AR mice with injection of PBS (AR + PBS group, 7 mice). After injection of AMSC-exos and PBS, symptoms were observed in mice and inflammatory factors including IL-4, IL-5, IFN- $\gamma$  and Ig-E were determined. Mice were sacrificed, nasal mucosa was collected for HE staining and qRT-PCR.

**Results:** After injection of AMSC-exos, compared with the AR + PBS group, symptoms were significantly improved, inflammatory factor levels were significantly decreased, disturbed and thickened mucosal layer was relieved, and the numbers of goblet cells and eosinophils were reduced in the AR + AMSC-exos group.

**Conclusion:** AMSC-exos can improve symptoms and inflammatory level in the AR mice.

## 1. Introduction

Allergic rhinitis (AR), a non-infectious inflammatory disease occurring in the nasal mucosa, is a chronic disease affecting human health in the world [1]. AR is an allergic disease mediated by immunoglobulin E (IgE) and caused by various immune cells, such as mast cells and eosinophils [2]. AR pathogenesis is related to IgE activation and the release of inflammatory factors, so inhibiting the inflammation in the nasal mucosa is a potential therapeutic regimen for AR [2].

Stem cells, primitive cells, have the abilities of self-replication and multi-directional differentiation. Stem cells are characterised by long-term self-replication without aging, differentiation into one or several specific somatic cells [3,4], and expression of differentiated tissue function [5,6]. Mesenchymal stem cells (MSCs) also can inhibit T lymphocytes, B lymphocytes, dendritic cells and natural killer cells [7,8]. MSCs exhibit homing to the injured and inflammatory areas. MSCs promote growth and differentiation of diseased cells as

<sup>\*</sup> Corresponding author. Number one, Constructive East Road, Erqi District, Zhengzhou, 450052, China.  
E-mail address: [yanghaibo0129@sina.com.cn](mailto:yanghaibo0129@sina.com.cn) (Y. Wang).

they can exert antiapoptotic, angiogenic and anti-inflammatory functions by producing cytokines, growth factors and chemokines as well as expressing extracellular matrix receptors on the cell surface [9]. Adipose-derived mesenchymal stem cells (AMSCs) are widely used in the field of modern medicine because its source is rich, taking materials is simple, culture is easy without the problems of tissue matching and immune rejection [10]. Compared with MSCs, MSC-derived exosomes have more advantages, such as low immunogenicity, easy storage and high biological safety [11–13]. Exosomes, extracellular vesicles with a diameter of 30–150 nm, are secreted by many types of cells. Its size is similar to nanoparticle, so exosomes are more likely to reach target sites to play their roles. The exosome contains various cytosolic proteins, lipids and nucleic acids, so it is a very promising cell-free therapeutic drug for autoimmune diseases [14,15]. At present, there are many therapeutic regimens for AR, but their therapeutic effects are not better. Therefore, it is important to find new therapeutic targets by exploring AR immune regulation. The aim of this study was to explore whether adipose mesenchymal stem cell-derived exosomes (AMSC-exos) can play a role in the treatment of AR.

## 2. Materials and methods

All study methods were approved by the Ethics Committee of the First Affiliates Hospital of Zhengzhou University (2023-yyy-030), and followed national standards for the care and use of laboratory animals.

### 2.1. Animals and cells

A total of 21 6 to 8-week male Balbc mice weighing between 20g and 30g [License No.: scxk (Beijing) 2019-0008] were purchased from Beijing Hufukang Biotechnology Co., Ltd (Beijing, China). Human AMSCs were purchased from Guangzhou Saiye Biotechnology Co., LTD (Guangzhou, China).

### 2.2. Reagents and equipments

PBS/RPMI-1640 medium, DMEM medium, fetal bovine serum, double-antibody and 0.25 % trypsin were purchased from Gibco (New York, New York State, USA). EXO-free serum was purchased from SBI (Palo Alto, California, USA). Ninety six-well plates were from Corning (New York, New York State, USA). Thermostatic incubator was provided by Eppendorf (Hamburg, Germany). Ultracentrifuge was purchased from Himac (Tokyo, Japan). Transmission electron microscopy (TEM) was from Hitachi (Tokyo, Japan) and optimal cutting temperature compound (OCT) was provided by Leica (Wetzlar, Germany).

### 2.3. Extraction and identification for AMSC-exos

When AMSCs were cultured to fourth or fifth passage, the medium was collected followed by centrifugation at 300g for 10 min at 4 °C, and then at 2000g for 10 min at 4 °C to obtain supernatant. The supernatant underwent ultracentrifugation at 10000g for 30 min at 4 °C and at 100000g for 70 min at 4 °C, respectively, to obtain transparent precipitation. The transparent precipitation was resuspended in 2000 µl of phosphate buffered saline (PBS) to obtain exosomes [16]. The exosome suspension (10–20 µl) was fixed using 2 % of paraformaldehyde and 2 % of glutaraldehyde, respectively, and then loaded on the surface of the carbon-coated copper mesh followed by negative staining using 2 % of uranyl acetate. The exosome morphology and exosome particles were observed by TEM and nanoparticle tracking analysis (NTA), respectively. Exosome surface-specific proteins, including CD9, CD63 and TSG101 were identified by Western blotting.

### 2.4. Establishment and grouping of AR mouse models

Ovalbumin (1 mg) and aluminum hydroxide (20 mg) were dissolved in 1 mL of saline, and then 200 ml of the mixture was injected into the intraperitoneal cavity of each mouse (a total of 14 mice) on the first, seventh, fourteenth and twenty first day, respectively. And then the mixture of ovalbumin (100 µg) and saline (20 µl) was dripped into each nostril for 14 days [17,18]. Mouse symptoms were observed and recorded within 15 min after the last nasal dripping. Subsequently, AR mouse models were divided into two group. One group was treated using AMSC-exos as AR + AMSC-exos group (7 mice) and another group was treated using PBS as AR + PBS group (7 mice).

### 2.5. Label-ling AMSC-exos and injecting them into AR mice by the mouse tail vein

Fluorescent dye was diluted to 10 times with PBS solution, and then the 10 µl of fluorescent dye was added into 90 µl of PBS to make 100 µl of dye working solution. The 100 µl of dye working solution was added to 1000 µl of exosome suspension followed by mixing in a vortex oscillator for 1 min at 37 °C. Thirty 30 min later, 10 ml of 1 X PBS was added, and then 200 µl of 1 X PBS was suspended and the sediment was the stained exosomes. The stained exosomes were injected into AP mice through the mouse tail vein, and then the AR mice were observed by living imaging system at 2h, 12h, 24h, 36h and 48h after injecting the stained exosomes.

### 2.6. Intervention

After the last nasal dripping, 20 µl of AMSC-exos (50 µg/ml) were injected into the tail vein in 7 AR mice once a day for 14 days as

AR + AMSC-exos group. In the same time, 20  $\mu$ l of PBS were injected into the tail vein in both 7 AR mice and 7 normal mice once a day for 14 days as AR + PBS group and normal + PBS group. Within 15 min after the last intervention, AR symptoms, such as scratching the nose, sneezing and runny nose, were observed and recorded in each group, and then killed. Peripheral blood and nasal mucosa were collected for determining the serum levels of IL-4, IL-5, IFN- $\gamma$  and IgE by enzyme linked immunosorbent assay (ELISA), and mRNA levels of IL-4, IL-5 and IFN- $\gamma$  by quantitative real-time PCR (qRT-PCR), as well as observing histological changes by HE staining.

## 2.7. Staining of mouse nasal mucosal tissue

After 2-week intervention, the mice in each group were killed by cervical dislocation. Nasal mucosal tissue was collected for HE and PAS staining. Pathological changes and infiltration of inflammatory cells were observed under light microscopy. The numbers of eosinophils and goblet cells were counted under optical microscope by randomly selecting 4 slices from each group and 4 regions in each slice, and then the average value of each group was calculated [19].

## 2.8. ELISA

After mice were killed, 1–1.5 ml of blood from each mouse orbital venous plexus were collected. After 4-h standing at room temperature, the venous blood was centrifugated at 1500 rpm for 20 min, and then 2–5  $\mu$ l of serum was used to determine the levels of IL-4, IL-5, IFN- $\gamma$  and IgE with ELISA kits. Testing was performed in triplicate for each sample.

## 2.9. qRT-PCR

The nasal mucosa was collected in each mouse, and then frozen in liquid nitrogen at  $-80^{\circ}\text{C}$ . The total RNA was extracted from nasal mucosa using Trizol. Reverse transcription reaction was performed using 1  $\mu$ g of RNA template, and mRNA levels of IL-4, IL-5 and IFN- $\gamma$  were detected by qRT-PCR.

## 2.10. Statistical analysis

Statistical analysis was performed using Graphpad Prism 8 software. The normality of data was analyzed by Shapiro-Wilk test. Measurement data were expressed as mean  $\pm$  standard deviation (Mean  $\pm$  SD). Comparison between multiple groups was performed using analysis of variance. Statistical significance was established at  $P < 0.05$ .

# 3. Results

## 3.1. Establishment and evaluation of AR mouse models

The scoring criteria for mouse runny nose, scratching the nose and sneezing are shown in Table 1. The total score over 5 will be regarded as successful modeling [17,18,20]. Mouse symptoms were observed and recorded within 15 min after the last nasal dripping. In the AR + AMSC-exos group and AR + PBS group, mice frequently scratched their noses, and exhibited continuous sneezing with a lot of nasal mucus. The scoring for mouse runny nose, scratching the nose and sneezing in the three groups before intervention are shown in Table 2. The scores of the AR + AMSC-exos group and AR + PBS group were all more than 5, indicating successful modeling.

## 3.2. Identification of the AMSC-exos

TEM showed that AMSC-exos, double layer vesicles, were round or oval with clear edges and a diameter of 50–150 nm (Fig. 1a). Western blotting indicated AMSC-exos specific membrane proteins, CD9 and CD63, as well as membrane conjugated protein TSG101 (Fig. 1b). NTA displayed that the concentration of sample AMSC-exos was  $8.6 \times 10^7$  particle/ml, the dilution ratio was 100, the original concentration was  $8.6 \times 10^9$  particle/ml, the peak particle diameter was 128.1 nm, the peak area ratio was 95.2 %, the average particle size was 131.2 nm, and the exosomes were basically in the distribution range of 30–200 nm (Fig. 2).

## 3.3. Biodistribution of AMSC-exos in the AR mice receiving tail vein injection of stained AMSC-exos

The living imaging system indicated no marked fluorescence at 2 h, a little fluorescence in the abdomen at 12 h, as well as obvious fluorescence in the chest at 24 h, in the neck at 36 h and in the nose and lips at 48 h after injecting stained AMSC-exos (Fig. 3).

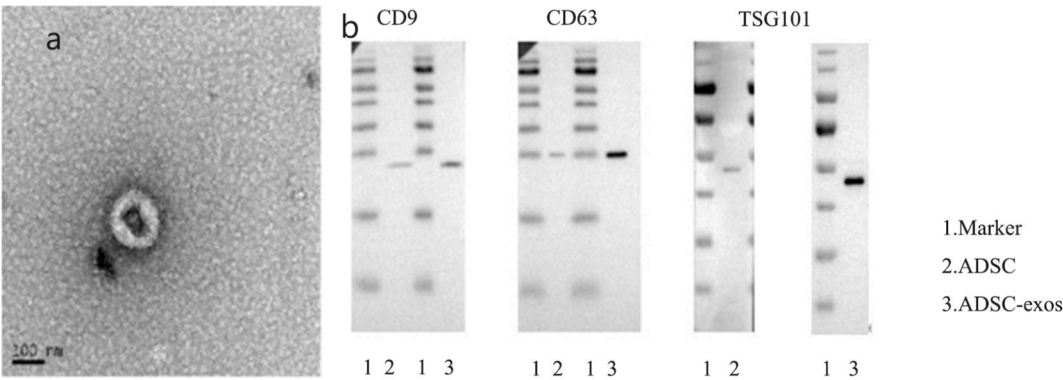
**Table 1**  
Scoring criteria for mouse runny nose, scratching nose and sneezing.

| Scores | Runny nose                         | Scratching nose | Sneezing |
|--------|------------------------------------|-----------------|----------|
| 1      | Runny nose to the front nostrils   | 1–5             | 1–3      |
| 2      | Runny nose over the front nostrils | 6–15            | 4–10     |
| 3      | Runny nose covering mouse face     | >16             | >11      |

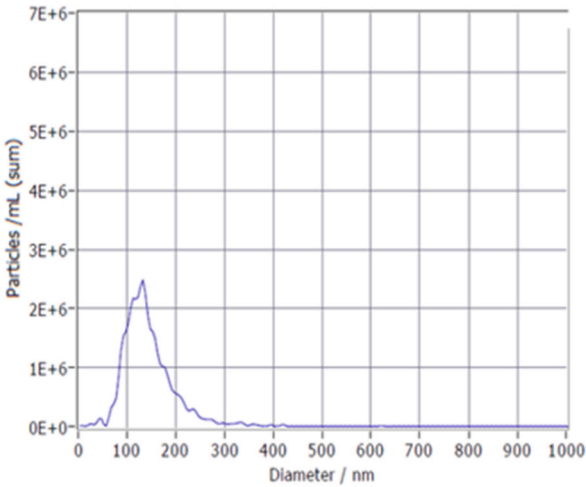
**Table 2**  
The scoring for mouse runny nose, scratching nose and sneezing in the three groups before intervention.

| Groups         | Runny nose | Scratching nose | Sneezing |
|----------------|------------|-----------------|----------|
| Normal + PBS   | 0          | 1               | 1        |
| AR + AMSC-exos | 2          | 3               | 2.43     |
| AR + PBS       | 2          | 2.86            | 2.14     |

Notes: PBS: Phosphate buffer saline; AR: Allergic rhinitis; AMSC-exos: adipose mesenchymal stem cell-derived exosomes.



**Fig. 1.** Identification of the AMSC-exos by transmission electron microscope (scale = 100 nm) and specific proteins. Notes: a: AMSC-exos; b: specific membrane proteins and membrane conjugated protein of AMSC-exos; 1: marker; 2: control group (ADSC); 3: sample (AMSC-exos); AMSC-exos: adipose mesenchymal stem cell-derived exosomes.



**Fig. 2.** Concentration profile of AMSC-exos. Notes: AMSC-exos: adipose mesenchymal stem cell-derived exosomes.

3.4. Improvement of AR symptoms in the AR + AMSC-exos group

Within 15 min after the last intervention, AR symptoms, such as scratching the nose, sneezing and runny nose, were observed and the frequencies of scratching the nose and sneezing were recorded in each group (Table 3).

3.5. Influence of AMSC-exos on serum levels of IL-4, IL-5, IFN-  $\gamma$  and IgE

ELISA indicated that the serum levels of IL-4, IL-5, IFN-  $\gamma$  and IgE were significantly decreased in the AR + AMSC-exos group as compared with the AR + PBS group ( $P < 0.0005$ , Table 4)

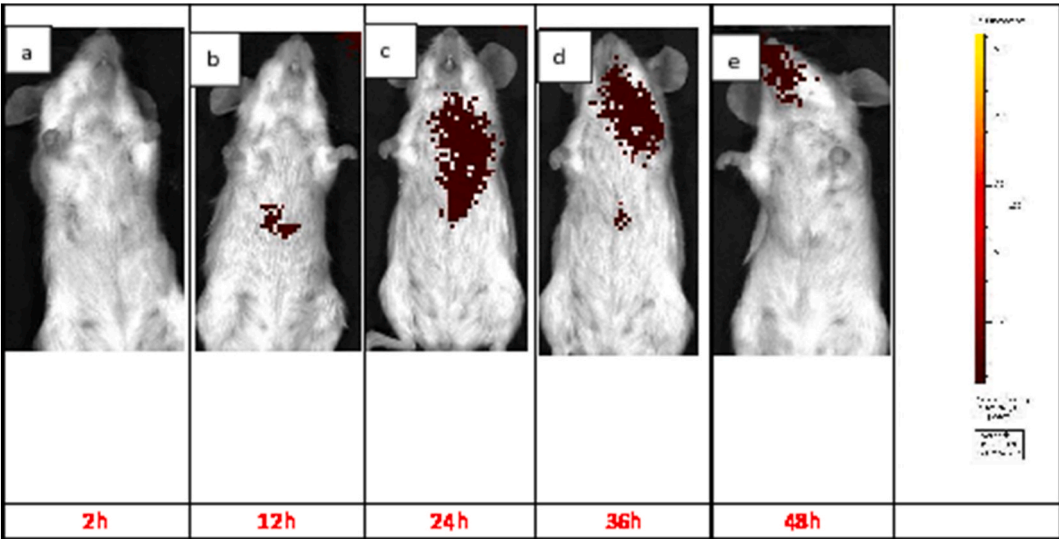


Fig. 3. Biodistribution of AMSC-exos in the AR mice in different time points. Notes: a: at 2h; b: at 12h; c: at 24h; d: at 36h; and e: at 48h.

**Table 3**  
Frequencies of scratching the nose and sneezing in each group after the last intervention (Mean  $\pm$  SD).

| Groups         | Scratching nose               | Sneezing                      |
|----------------|-------------------------------|-------------------------------|
| Normal + PBS   | 0.86 $\pm$ 1.355 <sup>a</sup> | 2.29 $\pm$ 2.250 <sup>a</sup> |
| AR + AMSC-exos | 7.71 $\pm$ 2.914 <sup>a</sup> | 4.71 $\pm$ 1.278 <sup>a</sup> |
| AR + PBS       | 25.86 $\pm$ 6.243             | 13.57 $\pm$ 3.886             |

<sup>a</sup> indicates  $P < 0.0001$  as compared with the AR + PBS group; PBS: Phosphate buffer saline; AR: Allergic rhinitis; AMSC-exos: adipose mesenchymal stem cell-derived exosomes.

3.6. Influence of AMSC-exos on mRNA levels of IL-4, IL-5 and IFN- $\gamma$  in mouse nasal mucosa

qRT-PCR indicated that the mRNA levels of IL-4, IL-5 and IFN- $\gamma$  in mouse nasal mucosa were significantly lower in the AR + AMSC-exos group and normal + PBS group than in the AR + PBS group ( $P < 0.0001$ , Table 5)

3.7. Pathology of mouse nasal mucosa tissue in each group

The mucosal epithelial layer of mouse nasal cavity was intact with mild eosinophil infiltration, but without tissue gap edema or vascular dilation in the normal + PBS group (Fig. 4a). A large amount of cilia in the mouse nasal mucosa peeled off with obvious interstitial edema, small blood vessel dilation and severe eosinophil infiltration in the AR + PBS group (Fig. 4c). Compared with the AR + PBS group, eosinophil infiltration was significantly relieved in the AR + AMSC-exos group ( $P = 0.003$ , Fig. 4b–Table 6).

In PAS staining, light blue was the nasal mucosa background, and purplish red was goblet cell. A few goblet cells were seen in the epithelial layer of mouse nasal mucosa in the normal + PBS group (Fig. 5a). In the AR + PBS group, there were a large number of goblet cells with obvious cytoplasmic hyperplasia and hypertrophy, and even with a typical high footed cup-shaped appearance (Fig. 5c). Compared with the AR + PBS group, the number of goblet cells was significantly reduced in the AR + AMSC-exos group ( $P = 0.004$ , Fig. 5b–Table 6).

**Table 4**  
Serum levels of IL-4, IL-5, IFN- $\gamma$  and IgE in the three groups after intervention (Mean  $\pm$  SD).

| Groups         | IL-4                           | IL-5                           | INF- $\gamma$                   | Ig-E                           |
|----------------|--------------------------------|--------------------------------|---------------------------------|--------------------------------|
| Normal + PBS   | 21.42 $\pm$ 0.780 <sup>a</sup> | 45.17 $\pm$ 0.350 <sup>a</sup> | 205.67 $\pm$ 0.697 <sup>a</sup> | 88.84 $\pm$ 1.981 <sup>a</sup> |
| AR + AMSC-exos | 40.27 $\pm$ 0.284 <sup>a</sup> | 47.15 $\pm$ 0.184 <sup>a</sup> | 354.84 $\pm$ 2.911 <sup>a</sup> | 83.00 $\pm$ 5.956 <sup>a</sup> |
| AR + PBS       | 54.20 $\pm$ 0.417              | 102.74 $\pm$ 0.361             | 387.18 $\pm$ 4.928              | 169.20 $\pm$ 6.627             |

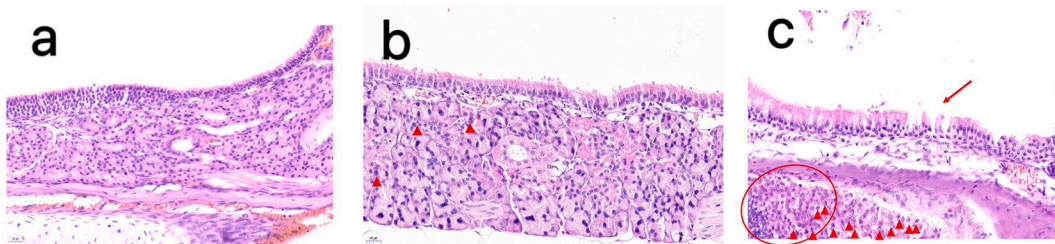
<sup>a</sup> indicates  $P < 0.0005$  as compared with the AR + PBS group; PBS: Phosphate buffer saline; AR: Allergic rhinitis; AMSC-exos: adipose mesenchymal stem cell-derived exosomes.



**Table 5**  
mRNA levels of IL-4, IL-5 and IFN- $\gamma$  in the three groups after intervention (Mean  $\pm$  SD).

| Groups         | IL-4                             | IL-5                             | INF- $\gamma$                   |
|----------------|----------------------------------|----------------------------------|---------------------------------|
| Normal + PBS   | 1.015 $\pm$ 0.0034 <sup>a</sup>  | 1.035 $\pm$ 0.0025 <sup>a</sup>  | 1.010 $\pm$ 0.0261 <sup>a</sup> |
| AR + AMSC-exos | 65.805 $\pm$ 0.6939 <sup>a</sup> | 12.905 $\pm$ 0.2806 <sup>a</sup> | 1.215 $\pm$ 0.0251 <sup>a</sup> |
| AR + PBS       | 89.013 $\pm$ 1.8039              | 20.570 $\pm$ 0.5167              | 1.428 $\pm$ 0.0065              |

<sup>a</sup> indicates  $P < 0.0001$  as compared with the AR + PBS group; PBS: Phosphate buffer saline; AR: Allergic rhinitis; AMSC-exos: adipose mesenchymal stem cell-derived exosomes.

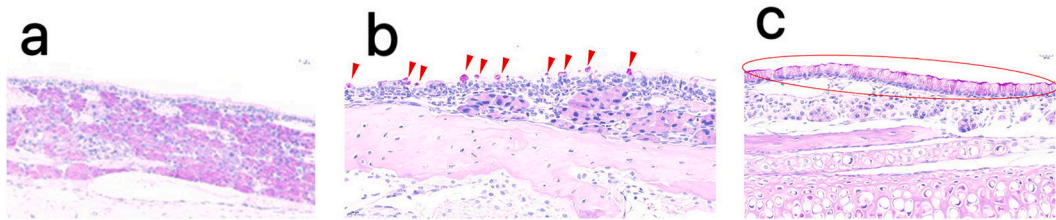


**Fig. 4.** HE staining of mouse nasal mucosa in each group 400  $\times$   
Notes: a: Normal + PBS group; b: AR + AMSC-exos group; c: AR + PBS group. The arrow in Fig. 3c indicates exfoliated cilia. The triangle and circle in Fig. 3c indicate eosinophil infiltration. PBS: Phosphate buffer saline; AR: Allergic rhinitis; AMSC-exos: adipose mesenchymal stem cell-derived exosomes.

**Table 6**  
Number of eosinophils and goblet cells in the epithelial layer of mouse nasal mucosa after intervention (Mean  $\pm$  SD).

| Items        | Normal + PBS group | AR + AMSC-exos group           | AR + PBS group    |
|--------------|--------------------|--------------------------------|-------------------|
| Eosinophils  | 1.50 $\pm$ 0.806   | 20.17 $\pm$ 1.537 <sup>a</sup> | 40.64 $\pm$ 1.542 |
| Goblet cells | 5.17 $\pm$ 0.401   | 14.67 $\pm$ 1.498 <sup>a</sup> | 22.50 $\pm$ 1.118 |

<sup>a</sup> indicates  $P < 0.05$  as compared with the AR + PBS group; PBS: Phosphate buffer saline; AR: Allergic rhinitis; AMSC-exos: adipose mesenchymal stem cell-derived exosomes.



**Fig. 5.** PAS staining of mouse nasal mucosa in each group 400  $\times$   
Notes: a: Normal + PBS group; b: AR + AMSC-exos group; c: AR + PBS group. Goblet cells are in the ellipse in Fig. 4c. The triangles in Fig. 4b indicate goblet cells. PBS: Phosphate buffer saline; AR: Allergic rhinitis; AMSC-exos: adipose mesenchymal stem cell-derived exosomes.

**4. Discussion**

AR, a chronic inflammatory disease occurring in the airways, is caused by many factors. AR is still one of the most common health problems due to its high incidence rate, complex etiology and long course of disease. AR has obvious nasal symptoms, such as nasal obstruction, paroxysmal sneezing, a lot of clear nasal mucus and nasal itching [1,21,22]. These symptoms interfere with normal life, affecting people's quality of life. AR pathogenesis are associated with many factors, but immunology has always been regarded as a focus for AR pathogenesis [23–25]. At present, the treatment for AR is only limited to symptom relief, and AR is not able be cured. This aim of this study was to observe the effect of AMSC-exos on AR in mice, finding new therapeutic regimens for AR.

MSCs have self-renewal and multiple differentiation potentials with strong self reproduction ability and automatic homing characteristics [26,27]. In addition, MSCs also have immune regulatory functions, regulating T cell differentiation and proliferation by cell communication and cytokine release [18,20,28]. There have been many studies on the relationship between MSCs and allergic diseases, such as asthma, AR, allergic dermatitis, etc [13,14,29,30]. However, increasing evidence suggests that the immunosuppressive effects of MSCs are mainly from MSC-derived extracellular vesicles, exosomes [10–12,14,26,31,32]. This is also confirmed by miRNA

sequencing and bioinformatics analysis of MSC-derived exosomes. MSC-derived exosomes can inhibit lymphocyte proliferation, participate in antigen presentation, promote damage repair, and regulate immune cell phenotype and function [33–36]. Due to the limitations of stem cell therapy, MSC-derived exosomes bring hope to treat many diseases that were even previously incurable.

In this study, the living imaging system indicated no marked fluorescence at 2 h, a little fluorescence in the abdomen at 12 h, as well as obvious fluorescence in the chest at 24 h, in the neck at 36 h and in the nose and lips at 48 h after injecting stained AMSC-exos. This suggested that there was the AMSC-exo distribution in the mouse nasal cavity. This study also showed that AMSC-exos effectively alleviated nasal symptoms, such as sneezing, runny nose and scratching the nose in AR mice. HE staining indicated that compared with the AR + PBS group, nasal mucosal structural disorder, thickened mucosal layer, and increased goblet cells and eosinophils were relieved in the AR + AMSC-exos group. ELISA displayed that compared with the AR + PBS group, the serum levels of IL-4, IL-5, IFN- $\gamma$  and IgE were significantly decreased in the AR + AMSC-exos group. The mRNA levels of IL-4, IL-5 and IFN- $\gamma$  in mouse nasal mucosa were in line with the serum levels of IL-4, IL-5 and IFN- $\gamma$ .

The imbalance between Th1 and Th2 cells is an important pathogenesis of AR [37,38]. Overactivation of Th2 cells may increased release of cytokines, including IL-4, IL-5 and IL-10, leading to AR. MSC-exos can inhibit the maturation and activation of DC cells, exert protective effect and anti-inflammatory effect by reducing NK cell recruitment [39,40]. Besides anti-inflammatory proteins, MSC-exos also contain many miRNAs with anti-inflammatory functions [39,40]. MSC-exos can specifically recognize CD4<sup>+</sup>T cells as well as reduce Th2 cells and secretion of Th2 cell-related inflammatory factors, suggesting that MSC-exos are associated with the differentiation of CD4<sup>+</sup>T cells in AR [41,42]. In this study, compared with the AR + PBS group, the serum levels of IL-4, IL-5, IFN- $\gamma$  and IgE were significantly decreased in the AR + AMSC-exos group, suggesting that AMSC-exos may have the potential to correct Th1/Th2 imbalance. The inflammatory regulatory effects of AMSC-exos may be more complex. It may be involved in the inhibition of T cell differentiation, intrinsic lymphocyte regulation, macrophage and lymphocyte regulation, and macrophage polarization [34,43,44].

This study confirmed that the AMSC-exos might reduce the levels of IL-4, IL-5, Ig-E and IFN- $\gamma$ , and alleviate allergic symptoms in AR mice. This may be caused by correcting the Th1/Th2 cell imbalance, but the exact mechanism remains to be further explored. This study provides an experimental basis for AMSC-exos as a new therapeutic regimen for allergic diseases and AR.

#### CRediT authorship contribution statement

**Xiaojie Xu:** Writing – original draft, Methodology, Investigation, Data curation. **Chang Li:** Methodology, Data curation. **Qin Qin:** Methodology, Investigation, Data curation. **Feiyan Han:** Software, Data curation. **Ying Wang:** Funding acquisition, Conceptualization.

#### Ethics

All study methods were approved by the Ethics Committee of the First Affiliates Hospital of Zhengzhou University (2023-yyy-030), and followed national standards for the care and use of laboratory animals.

#### Data availability statement

All data supporting the findings are included in this article. The datasets during the study that are not presented in this article are available from the corresponding author on reasonable request.

#### Funding

This study was supported by the Young and middle-aged Health Science and Technology Innovation Talent Project of Henan Province (No: LJRC2023009), the Henan Provincial Medical Science, Technology Research Project (No: SBGJ202302064) and Henan Province Key Research and Development Project (241111311100).

#### Declaration of competing interest

The authors declare that they have no known competing financial interests or personal relationships that could have appeared to influence the work reported in this paper.

#### Acknowledgement

Not applicable.

#### Appendix A. Supplementary data

Supplementary data to this article can be found online at <https://doi.org/10.1016/j.heliyon.2024.e41340>.

## References

- [1] J. Bousquet, J.M. Anto, C. Bachert, I. Baiardini, S. Bosnic-Anticevich, Canonica G. Walter, et al., Allergic rhinitis, *Nat Rev Dis Primers* 6 (2020) 95, <https://doi.org/10.1038/s41572-020-00227-0>.
- [2] D.I. Bernstein, G. Schwartz, J.A. Bernstein, Allergic rhinitis: mechanisms and treatment, *Immunol Allergy Clin North Am* 36 (2016) 261–278, <https://doi.org/10.1016/j.jiac.2015.12.004>.
- [3] C. Yang, J. Li, H. Lin, C. Zhao, C. Zheng, Nasal mucosa derived-mesenchymal stem cells from mice reduce inflammation via modulating immune responses, *PLoS One* 10 (2015) e0118849, <https://doi.org/10.1371/journal.pone.0118849>.
- [4] M. Wang, N. Zhao, C. Wang, Z.B. Jin, L. Zhang, Immunomodulatory properties of mesenchymal stem cells: a potential therapeutic strategy for allergic rhinitis, *Allergy* 78 (2023) 1425–1440, <https://doi.org/10.1111/all.15729>.
- [5] S. Işık, M. Karaman, A. Adan, M. Kiray, H.A. Bağrıyanık, Ş.Ç. Sözen, et al., Intraperitoneal mesenchymal stem cell administration ameliorates allergic rhinitis in the murine model, *Eur. Arch. Oto-Rhino-Laryngol.* 274 (2017) 197–207, <https://doi.org/10.1007/s00405-016-4166-3>.
- [6] R. Keyhanmanesh, R. Rahbarghazi, M.R. Aslani, M. Hassanpour, M. Ahmadi, Systemic delivery of mesenchymal stem cells condition media in repeated doses acts as magic bullets in restoring IFN- $\gamma$ /IL-4 balance in asthmatic rats, *Life Sci.* 212 (2018) 30–36, <https://doi.org/10.1016/j.lfs.2018.09.049>.
- [7] N. Zhao, Y. Liu, H. Liang, X. Jiang, Bone marrow-derived mesenchymal stem cells reduce immune reaction in a mouse model of allergic rhinitis, *Am J Transl Res* 8 (2016) 5628–5636.
- [8] A.T. Özdemir, R.B. Özgül Özdemir, C. Kırmaz, A.E. Sarıboyacı, Z.S. Ünal Halbutoğulları, C. Özel, et al., The paracrine immunomodulatory interactions between the human dental pulp derived mesenchymal stem cells and CD4 T cell subsets, *Cell. Immunol.* 310 (2016) 108–115, <https://doi.org/10.1016/j.cellimm.2016.08.008>.
- [9] M. Goodwin, V. Sueblinvong, P. Eisenhauer, N.P. Ziats, L. LeClair, M.E. Poynter, et al., Bone marrow-derived mesenchymal stromal cells inhibit Th2-mediated allergic airways inflammation in mice, *Stem Cell.* 29 (2011) 1137–1148, <https://doi.org/10.1002/stem.656>.
- [10] M. Mendt, K. Rezvani, E. Shpall, Mesenchymal stem cell-derived exosomes for clinical use, *Bone Marrow Transplant.* 54 (2019) 789–792, <https://doi.org/10.1038/s41409-019-0616-z>.
- [11] B. Torrecillas-Baena, V. Pulido-Escribano, G. Dorado, M.Á. Gálvez-Moreno, M. Camacho-Cardenosa, A. Casado-Díaz, Clinical potential of mesenchymal stem cell-derived exosomes in bone regeneration, *J. Clin. Med.* 12 (2023) 4385, <https://doi.org/10.3390/jcm12134385>.
- [12] J. Zou, W. Yang, W. Cui, C. Li, C. Ma, X. Ji, et al., Therapeutic potential and mechanisms of mesenchymal stem cell-derived exosomes as bioactive materials in tendon-bone healing, *J. Nanobiotechnology* 21 (2023) 14, <https://doi.org/10.1186/s12951-023-01778-6>.
- [13] D.H. Ha, H.K. Kim, J. Lee, H.H. Kwon, G.H. Park, S.H. Yang, et al., Mesenchymal stem/stromal cell-derived exosomes for immunomodulatory therapeutics and skin regeneration, *Cells* 9 (2020) 1157, <https://doi.org/10.3390/cells9051157>.
- [14] C.R. Harrell, N. Jovicic, V. Djonov, N. Arsenijevic, V. Volarevic, Mesenchymal stem cell-derived exosomes and other extracellular vesicles as new remedies in the therapy of inflammatory diseases, *Cells* 8 (2019) 1605, <https://doi.org/10.3390/cells8121605>.
- [15] D.G. Phinney, M.F. Pittenger, Concise review: MSC-derived exosomes for cell-free therapy, *Stem Cell.* 35 (4) (2017) 851–858, <https://doi.org/10.1002/stem.2575>.
- [16] B. Zhang, Y. Yin, R.C. Lai, S.S. Tan, A.B. Choo, S.K. Lim, Mesenchymal stem cells secrete immunologically active exosomes, *Stem Cells Dev* 23 (2014) 1233–1244, <https://doi.org/10.1089/scd.2013.0479>.
- [17] N. Ebrahim, Y.M.H. Mandour, A.S. Farid, E. Nafie, A.Z. Mohamed, M. Safwat, et al., Adipose tissue-derived mesenchymal stem cell modulates the immune response of allergic rhinitis in a rat model, *Int. J. Mol. Sci.* 20 (2019) 873, <https://doi.org/10.3390/ijms20040873>.
- [18] L. Restimulia, S. Ilyas, D. Munir, A. Putra, T. Madiadipoera, F. Farhat, et al., Rats' umbilical-cord mesenchymal stem cells ameliorate mast cells and Hsp70 on ovalbumin-induced allergic rhinitis rats, *Med. Glas.* 19 (2022), <https://doi.org/10.17392/1421-21>. Online ahead of print.
- [19] G. Usha, I. Pal, S. Kumar, B. Mondal, G. Basu, Assessment of nasal smear eosinophil counts in allergic rhinitis: how useful is it? *Indian J. Otolaryngol. Head Neck Surg.* 74 (2022) 540–546, <https://doi.org/10.1007/s12070-022-03109-x>.
- [20] H. Tang, X. Han, T. Li, Y. Feng, J. Sun, Protective effect of miR-138-5p inhibition modified human mesenchymal stem cell on ovalbumin-induced allergic rhinitis and asthma syndrome, *J. Cell Mol. Med.* 25 (2021) 5038–5049, <https://doi.org/10.1111/jcmm.16473>.
- [21] S.K. Wise, C. Damask, L.T. Roland, C. Ebert, J.M. Levy, S. Lin, et al., International consensus statement on allergy and rhinology: allergic rhinitis - 2023, *Int Forum Allergy Rhinol* 13 (2023) 293–859, <https://doi.org/10.1002/alf.23090>.
- [22] C.F. Schuler Iv, J.M. Montejo, Allergic rhinitis in children and adolescents, *Pediatr Clin North Am* 66 (2019) 981–993, <https://doi.org/10.1016/j.pcl.2019.06.004>.
- [23] M. Benson, M. Adner, L.O. Cardell, Cytokines and cytokine receptors in allergic rhinitis: how do they relate to the Th2 hypothesis in allergy? *Clin. Exp. Allergy* 31 (2001) 361–367, <https://doi.org/10.1046/j.1365-2222.2001.01045.x>.
- [24] M. Yang, L. Sun, D. Zhu, C. Meng, J. Sha, Recent advances in understanding the effects of T lymphocytes on mucosal barrier function in allergic rhinitis, *Front. Immunol.* 14 (2023) 1224129, <https://doi.org/10.3389/fimmu.2023.1224129>.
- [25] M. Mesdaghi, M. Voddjani, E. Salehi, J. Hadjati, A. Sarrafnejad, K. Bidad, et al., Natural killer cells in allergic rhinitis patients and nonatopic controls, *Int. Arch. Allergy Immunol.* 153 (2010) 234–238, <https://doi.org/10.1159/000314363>.
- [26] Z. Luo, Y. Sun, B. Qi, J. Lin, Y. Chen, Y. Xu, et al., Human bone marrow mesenchymal stem cell-derived extracellular vesicles inhibit shoulder stiffness via let-7a/Tgfb1 axis, *Bioact. Mater.* 17 (2022) 344–359, <https://doi.org/10.1016/j.bioactmat.2022.01.016>.
- [27] I.S. Park, J.H. Kim, J.S. Bae, D.K. Kim, J.H. Mo, The supernatant of tonsil-derived mesenchymal stem cell has antiallergic effects in allergic rhinitis mouse model, *Mediators Inflamm* 2020 (2020) 6982438, <https://doi.org/10.1155/2020/6982438>.
- [28] M. Budoni, A. Fierabracci, R. Luciano, S. Petrini, V. Di Ciommo, M. Muraca, The immunosuppressive effect of mesenchymal stromal cells on B lymphocytes is mediated by membrane vesicles, *Cell Transplant.* 22 (2013) 369–379, <https://doi.org/10.3727/096368911x582769>.
- [29] J.L. Brożek, J. Bousquet, I. Agache, A. Agarwal, C. Bachert, S. Bosnic-Anticevich, et al., Allergic rhinitis and its impact on asthma (ARIA) guidelines-2016 revision, *J. Allergy Clin. Immunol.* 140 (2017) 950–958, <https://doi.org/10.1016/j.jaci.2017.03.050>.
- [30] T.B. Casale, M.S. Dykewicz, Clinical implications of the allergic rhinitis-asthma link, *Am. J. Med. Sci.* 327 (2004) 127–138, <https://doi.org/10.1097/00000441-200403000-00004>.
- [31] L. Fan, J. Dong, X. He, C. Zhang, T. Zhang, Bone marrow mesenchymal stem cells-derived exosomes reduce apoptosis and inflammatory response during spinal cord injury by inhibiting the TLR4/MyD88/NF- $\kappa$ B signaling pathway, *Hum. Exp. Toxicol.* 40 (2021) 1612–1623, <https://doi.org/10.1177/09603271211003311>.
- [32] L.L. de Castro, D.G. Xisto, J.Z. Kitoko, F.F. Cruz, P.C. Olsen, P.A.G. Redondo, et al., Human adipose tissue mesenchymal stromal cells and their extracellular vesicles act differentially on lung mechanics and inflammation in experimental allergic asthma, *Stem Cell Res. Ther.* 8 (2017) 151, <https://doi.org/10.1186/s13287-017-0600-8>.
- [33] Z. Zheng, Y. Yu, A review of recent advances in exosomes and allergic rhinitis, *Front. Pharmacol.* 13 (2022) 1096984, <https://doi.org/10.3389/fphar.2022.1096984>.
- [34] X.Q. Liu, Y.Q. Peng, L.X. Huang, C.G. Li, P.P. Kuang, D.H. Chen, et al., Dendritic cells mediated by small extracellular vesicles derived from MSCs attenuated the IL2 activity via PGE2 in patients with allergic rhinitis, *Stem Cell Res. Ther.* 14 (2023) 180, <https://doi.org/10.1186/s13287-023-03408-2>.
- [35] J. Tian, Q. Zhu, Y. Zhang, Q. Bian, Y. Hong, Z. Shen, et al., Olfactory ecto-mesenchymal stem cell-derived exosomes ameliorate experimental colitis via modulating Th1/Th17 and treg cell responses, *Front. Immunol.* 11 (2020) 598322, <https://doi.org/10.3389/fimmu.2020.598322>.
- [36] E.I. Buzas, The roles of extracellular vesicles in the immune system, *Nat. Rev. Immunol.* 23 (2023) 236–250, <https://doi.org/10.1038/s41577-022-00763-8>.
- [37] H. Shirasaki, E. Kanaizumi, N. Seki, T. Himi, Correlation of local FOXP3-expressing T cells and Th1-Th2 balance in perennial allergic nasal mucosa, *Int J Otolaryngol.* 2011 (2011) 259867, <https://doi.org/10.1155/2011/259867>.




- [38] W. Li, C.Y. Cai, J.J. Zeng, Mesenchymal stem cell-derived exosome-containing Linc00632 regulates GATA binding protein-3 expression in allergic rhinitis by interacting with enhancer of zeste homolog 2 to inhibit T helper cell 2 differentiation, *Int. Arch. Allergy Immunol.* 183 (2022) 235–245, <https://doi.org/10.1159/000518950>.
- [39] Y.Q. Peng, Z.C. Wu, Z.B. Xu, S.B. Fang, D.H. Chen, H.Y. Zhang, et al., Mesenchymal stromal cells-derived small extracellular vesicles modulate DC function to suppress Th2 responses via IL-10 in patients with allergic rhinitis, *Eur. J. Immunol.* 52 (2022) 1129–1140, <https://doi.org/10.1002/eji.202149497>.
- [40] R. Blazquez, F.M. Sanchez-Margallo, O. de la Rosa, W. Dalemans, V. Alvarez, R. Tarazona, et al., Immunomodulatory potential of human adipose mesenchymal stem cells derived exosomes on in vitro stimulated T cells, *Front. Immunol.* 5 (2014) 556, <https://doi.org/10.3389/fimmu.2014.00556>.
- [41] Y.Q. Peng, Z.L. Qin, S.B. Fang, Z.B. Xu, H.Y. Zhang, D. Chen, et al., Effects of myeloid and plasmacytoid dendritic cells on ILC2s in patients with allergic rhinitis, *J. Allergy Clin. Immunol.* 145 (2020) 855–867.e858, <https://doi.org/10.1016/j.jaci.2019.11.029>.
- [42] J.D. Burke, H.A. Young, IFN- $\gamma$ : a cytokine at the right time, is in the right place, *Semin. Immunol.* 43 (2019) 101280, <https://doi.org/10.1016/j.smim.2019.05.002>.
- [43] Q. Meng, P. Li, Y. Li, J. Chen, L. Wang, L. He, et al., Broncho-vaxom alleviates persistent allergic rhinitis in patients by improving Th1/Th2 cytokine balance of nasal mucosa, *Rhinology* 57 (2019) 451–459, <https://doi.org/10.4193/Rhin19.161>.
- [44] J. Zhou J, Y. Lu, W. Wu, Y. Feng, HMSC-derived exosome inhibited Th2 cell differentiation via regulating miR-146a-5p/SERPINB2 pathway, *J Immunol Res* 2021 (2021) 6696525, <https://doi.org/10.1155/2021/6696525>.

**Update**

**Heliyon**

Volume 11, Issue 14, September 2025, Page

DOI: <https://doi.org/10.1016/j.heliyon.2025.e43880>



# Corrigendum to “Effect of adipose mesenchymal stem cell-derived exosomes on allergic rhinitis in mice”

Xiaojie Xu, Chang Li, Qin Qin, Feiyan Han, Ying Wang<sup>\*</sup>

*Nasal Department, The First Affiliated Hospital of Zhengzhou University, Zhengzhou, 450052, China*

In this article, the published name of the ethics committee and the legends for Figure 4 and Figure 5 require correction.

The original ethics approval statement can be found below:

“All study methods were approved by the Ethics Committee of the First Affiliates Hospital of Zhengzhou University (2023-yyy-030), and followed national standards for the care and use of laboratory animals.”

This version is now updated with the version reflecting the correct name of the ethics committee.

The correct ethics approval statement can be found below:

“All study methods were approved by the Ethics Committee for Experimental Animals of the Henan Provincial Key Laboratory of Hepatology Pharmacology (2023-yyy-030), and followed national standards for the care and use of laboratory animals.”

The original version of the legends for Figure 4 and Figure 5 can be found below:

“Fig. 4. HE staining of mouse nasal mucosa in each group 400×

Notes: a: Normal+PBS group; b: AR+AMSC-exos group; c: AR+PBS group. The arrow in Fig. 3c indicates exfoliated cilia. The triangle and circle in Fig. 3c indicate eosinophil infiltration. PBS: Phosphate buffer saline; AR: Allergic rhinitis; AMSC-exos: adipose mesenchymal stem cell-derived exosomes.”

“Fig. 5. PAS staining of mouse nasal mucosa in each group 400×

Notes: a: Normal+PBS group; b: AR+AMSC-exos group; c: AR+PBS group. Goblet cells are in the ellipse in Fig. 4c. The triangles in Fig. 4b indicate goblet cells. PBS: Phosphate buffer saline; AR: Allergic rhinitis; AMSC-exos: adipose mesenchymal stem cell-derived exosomes.”

The version is now updated with the version reflecting the correct legends.

The correct version of the legends for Figure 4 and Figure 5 can be found below:

“Fig. 4. HE staining of mouse nasal mucosa in each group 400×

Notes: a: Normal+PBS group; b: AR+AMSC-exos group; c: AR+PBS group. The arrow in Fig. 4c indicates exfoliated cilia. The triangle and circle in Fig. 4c indicate eosinophil infiltration. PBS: Phosphate buffer saline; AR: Allergic rhinitis; AMSC-exos: adipose mesenchymal stem cell-derived exosomes.”

“Fig. 5. PAS staining of mouse nasal mucosa in each group 400×

Notes: a: Normal+PBS group; b: AR+AMSC-exos group; c: AR+PBS group. Goblet cells are in the ellipse in Fig. 5c. The triangles in Fig. 5b indicate goblet cells. PBS: Phosphate buffer saline; AR: Allergic rhinitis; AMSC-exos: adipose mesenchymal stem cell-derived exosomes.”

The authors apologize for the errors.

DOI of original article: <https://doi.org/10.1016/j.heliyon.2024.e41340>.

<sup>\*</sup> Corresponding author.

E-mail address: [yanghaibo0129@sina.com.cn](mailto:yanghaibo0129@sina.com.cn) (Y. Wang).

<https://doi.org/10.1016/j.heliyon.2025.e43880>

Available online 16 September 2025

2405-8440/© 2025 The Author(s). Published by Elsevier Ltd. All rights are reserved, including those for text and data mining, AI training, and similar technologies.

### **Declaration of competing interest**

The authors declare that they have no known competing financial interests or personal relationships that could have appeared to influence the work reported in this paper.